

Florence Hannah Renée Orlik

PERSISTENT DENTO ALVEOLAR PAIN DISORDER :
DIAGNOSTIC AND TREATMENT

Universidade Fernando Pessoa – Faculdade de Ciências da Saúde

Porto - 2017

Florence Hannah Renée Orlik

PERSISTENT DENTO ALVEOLAR PAIN DISORDER :
DIAGNOSTIC AND TREATMENT

Universidade Fernando Pessoa – Faculdade de Ciências da Saúde

Porto - 2017

Florence Hannah Renée Orlik

PERSISTENT DENTO ALVEOLAR PAIN DISORDER :
DIAGNOSTIC AND TREATMENT

Monography presented to the University of Fernando
Pessoa as part of the requirements for obtaining a
Master's Degree in Dental Medicine

ACKNOWLEDGMENTS :

« Travaillez, prenez de la peine : C'est le fonds qui manque le moins.

Que le travail est un trésor! »

Jean de La Fontaine, Le laboureur et ses enfants

Thanks to my grannies for always being models of bravery for me.

Thanks to my brother, the light of my life, which illuminates me immutably ; divine spark presents thanks to my exceptional parents.

To my dear family, thank you for teaching me the love of hard work, to be always present and enthusiastic for all my projects and to love me as I am.

Thanks to my best friend, my crime partner, for these good and studious moments spent together.

Give thanks to our Lord, without Him no one is.

*« I will give thanks to you, Lord, with all my heart;
I will tell of all your wonderful deeds.
I will be glad and rejoice in you;
I will sing the praises of your name, O Most High. »*

*« The Lord reigns forever;
he has established his throne for judgment.
He rules the world in righteousness
and judges the peoples with equity.
The Lord is a refuge for the oppressed,
a stronghold in times of trouble. »*

David, Psalm 9 : 1-2, 7-9

ABSTRACT :

Pain is a universal sensation experienced at least once by all.

The management of pain can not be conceived without an overall support of the patient.

The multidisciplinary approach apprehend chronic pain according to a bio-psycho-social model, first on an evaluative approach and then on a treatment, often multimodal and rehabilitative .

This thesis will therefore articulate according to the proper approach of a consultation of chronic pain.

The first part of this thesis will focus on defining the different types of pain currently recognized, focusing particularly on idiopathic pain, of which the subject, the persistent dento-alveolar pain, is a new branch.

The second part is an evaluative and diagnosis phase which allows to exclude the other types of pain referred and to understand the patient as a whole in order to propose an adapted treatment.

The last part will focus on proposing a range of traditional and non-conventional medicines.

Keywords : pain, chronic pain, pharmacological treatment, non-pharmacological treatment, persistent dento alvolar pain

SUMÁRIO :

A dor é uma sensação universal experimentada pelo menos uma vez por todos.

O manejo da dor não pode ser concebido sem o contributo total do paciente.

A abordagem multidisciplinar apreende a dor crônica de acordo com um modelo bio-psico-social, primeiro numa abordagem avaliativa e depois num tratamento, muitas vezes multimodal e reabilitativo.

Esta tese articular-se-á, portanto, de acordo com a abordagem adequada de uma consulta de dor crônica.

A primeira parte desta tese incidirá na definição dos diferentes tipos de dor atualmente reconhecidos, com ênfase particularmente na dor idiopática, sendo que o sujeito, dor persistente dentoalveolar é um novo ramo.

A segunda parte é uma fase de avaliação e diagnóstico que permite excluir os outros tipos de dor referidos e compreender o paciente como um todo a fim de propor um tratamento adaptado.

A última parte centrar-se-á na proposta de uma gama de medicamentos tradicionais e não convencionais.

Palavras-Chave : dor, dor crônica, tratamento farmacológico, tratamento não farmacológico, dor dentoalveolar persistente

TABLE OF CONTENTS :

Part 1 : Introduction.....	1
Part 2 : Methodology.....	2
Part 3 : Development.....	2
I. Different pathophysiology origins of pain.....	2
1. Nociceptive pain.....	2
2. Neuropathic pain.....	3
3. Psychogenic pain.....	3
4. Idiopathic pain or dysfunctional pain.....	3
i. Atypical facial pain : AFP.....	4
ii. Atypical odontalgia : AO.....	4
iii. Stomatodynia.....	5
iv. Facial arthromyalgia.....	5
v. PDAP specificity.....	5
II. Diagnostics and evaluations.....	6
1. Diagnosis of neuropathic pain.....	6
2. Clinical evaluation of pain.....	7
III. Treatments.....	8
1. Pharmacological treatments.....	8
i. The analgesics.....	8
ii. Coanalgesics.....	9
iii. The antidepressants.....	9
iv. The antiepileptics.....	9
v. Local anesthetics.....	9
vi. The equimolecular mixture of oxygen and nitrous oxide : MEOPA.....	9
vii. Recent advances and rediscoveries.....	10
2. Non-pharmacological treatments.....	10
i. Bio-psychosocial therapy.....	11
ii. Cognitive Behavior Therapy.....	11

PERSISTENT DENTO ALVEOLAR PAIN DISORDER : DIAGNOSTIC AND TREATMENT

iii. The physical and physiological methods.....	12
iv. Neurostimulation / Neuromodulation.....	13
v. Neurosurgery.....	14
a. Direct nervous anastomosis.....	14
b. Graffes.....	14
Part 4 : Discussion / Conclusion.....	15
Part 5 : Bibliography.....	16
Part 6 : Annex.....	20
Part 7 : Copyrights.....	31

ABBREVIATIONS AND ACRONYMS :

PDAP : Persistent DentoAlveolar Pain disorder
IASP : International Association for the Study of Pain
PIE : Pain In Europe
% : percentage
ie : id est
painSTORY : pain Study Tracking Ongoing Responses for a Year
AFA : Atypical Facial Algia
AO : Atypical Odontalgia
DN4 : Neuropathic pain in 4 questions
VAS : Visual Analogue Scale
NPRS : Numeric Pain Rating Scale
SVS : Simple Verbal Scale
NPS : Neuropathic Pain Scale
NPSI : Neuropathic Pain Symptom Inventory
PQAS : Pain Quality Assessment Scale
SFMPQ-2 : Short Questionnaire McGill 2
MRI : Magnetic Resonance Imaging
WHO : World Health Organisation
NMDA : N-méthyl-D-aspartate
MEOPA : Equimolar Mixture of Oxygen and nitrogen Peroxide
N₂O : Nitrous Oxide
9-THC : delta 9-TétraHydroCannabinol
TRPV1 : Transient Receptor Potencial Vanilloïde 1
CBT : Cognitive Behavioral Therapy
TENS : Transcutaneous Electrical Nerve Stimulation
rTMS : repetitive Transcranial Magnetic Stimulation
DREZ : Dorsal Root Entry Zone
PGA : PolyGlycolique Acid
PLT : Potentialization Long Term

PART 1 : INTRODUCTION

Pain is an essential partner in odontology.

Pain is a sensation and an unpleasant emotional experience in response to actual or potential tissue involvement or described in these terms (IASP, 1989).

Its perception is the key to dental practice, to direct the practitioner, and to signal a danger to the patient. In contrast to acute pain, chronic pain lasts more than three months. Whether acute or chronic, pain prompts the patient sooner or later to consult (Delzangles, 2015).

According to the PIE survey carried out between 2002 and 2003 on more than 4800 people suffering from chronic pain, in 16 European countries, 19% of European adults say they suffer from chronic pain, ie 75 million Europeans and 18% of these patients have been suffering for more than 20 years. These patients have already been treated without success. It is therefore also an economic stake by the social costs induced.

More recently, the painSTORY survey, which interviewed 294 patients in 13 European countries in 2008-2009, revealed that 77% of chronic pain patients are adults aged 41 years and older, 72% of whom are women .

Professionals in the dental sector recognize a distinct clinical entity that manifests as a persistent, continuous painful symptom localized in the dentoalveolar region and that can not be explained in the context of other diseases or disorders (Nixdorf *et alii.*, 2012)

This entity has previously been named, with ambiguity, atypical odontalgia, phantom dental pain and neuropathic dental pain, and has been classified as a subset of persistent idiopathic pain or atypical facial pain.

According to a recent consensus involving clinical experts and methodologists, this entity has also been referred to as persistent dento-alveolar pain disorder, and diagnostic criteria have been proposed. (Nixdorf *et alii.*, 2012).

There is no "one" but "some" pains. They are characterized by the diversity of physiopathological mechanisms that can intervene according to their origin, nociceptive, neuropathic, mixed, idiopathic or psychogenic. It is essential to know the physiopathological

mechanisms of the pain because the treatment with an analgesic aim depends on it (Rostaing *et alii.*, 2010).

The management of people suffering from chronic pain is most often multidisciplinary: medicated, physical, psychocorporeal (Nizard *et alii.*, 2014).

Recently, the same mechanisms involved in the cerebral plasticity of pain and memory have been revealed (Laurent, Pickering, 2014).

Memorizing is a common property of the nervous system and the dental organ: the tooth and the brain have the same embryological origin. (Vereeck, 2004).

Thus, the patient who has benefited from "therapeutic education" plays a major role in the management of his pain.

Eventually, discovering genes involved in the perception of pain, knowing all the effects of the mind on pain can also lead to the development of new treatments and significantly alter how we treat pain (Wickelgren, 2011).

PART 2 : METHODOLOGY

The bibliographic review presented in this dissertation was obtained through research conducted online and at the medical and dental library of the University Paris 5. I used as the main data base "MEDLINE / Pubmed", with key words : "Chronic pain", "PDAP", "dental pain", « capsaicin », « bromelain » ..

The inclusion criteria are : complete and free articles published from 2011 to 2016, in English. Items that did not include relevant information were excluded.

PART 3 : DEVELOPMENT

I. Different pathophysiology origins of pain

1. Nociceptive pain

This pain activates the nociceptive system in response to a brief stimulus and do not cause any

tissue injuries. It is a short duration. Its function is an alarm signal to avoid dangerous situations to our physical integrity. This pain can be qualified as mechanical / physiological or inflammatory (Berquin, Grisart, 2016).

2. Neuropathic pain

It is a pain initiated or consequent to a primary lesion of the peripheral or central nervous system. This is an abnormal activity of the somatosensory nervous system. It often has a particular tone : burning, electrical sensation (Berquin, Grisart, 2016).

The main hypotheses of central pain refers to two classical concepts of the excitability increase of central nociceptive neurons : sensitization and / or disinhibition (Bouhassira *et alii.*, 2012).

The phantom limb pain is an extreme case of neuropathic pain. They persist for years in about 30% of patients. This is one of the most common causes of chronic pain syndrome. In amputees there is a functional reorganization of the somatotopic maps of the somatosensory cortex which tends to evolve over several years. Thus, neurons that have lost their original afferents respond to tactile stimulations of other parts of the body.

At the level of transmission of pain is a process of "central sensitization", which processes the sensory information and gives rise to phantom limb pains. It reduces the threshold of pain perception but promotes the development of chronic pain (Purves *et alii.* 2015).

3. Psychogenic pain

Also called « pain sine materia », it is the expression of a psychological conflict that the patient is not conscious of. It is only generated by psychopathological processes (Berquin, Grisart, 2016) .

4. Idiopathic pain or dysfunctional pain

These are chronic pain syndromes that are neither linked to a proven nerve injury nor to inflammatory processes. These pain syndromes include fibromyalgia, irritable bowel syndrome, complex regional pain syndrome type I, migraine headache, interstitial cystitis and idiopathic orofacial idiopathic pain (Warnsinck *et alii.*, 2015).

i. Atypical facial pain : AFP

Initially confused with classic trigeminal neuralgia, it is marked by a pain often very intense, localized to the mouth, to the maxillary or the face, and felt deeply in the bones of the face. It may have been preceded by accidental or more often surgical trauma. There is no real trigger zone or paroxysmal character even if the pain can be aggravated by mastication or phonation. Over time, the pain spreads to wider territories, without respecting the zones of innervation of the trigeminal or cervical branches. It is bilateralised in one third of the cases. Pain is sometimes associated with dysesthesia or allodynia. The presence of associated psychopathological signs is reported by all authors : depression, anxiety, carcinophobia, intense stress, presence of a family or occupational event destabilizing in the months preceding the onset of symptoms (Warnsinck *et alii.*, 2015).

ii. Atypical odontalgia : AO

It is a clinical form of atypical facial pain. Pain is localized to a tooth, the condition of which can not explain the existence of the symptomatology. Premolars and molars are the most concerned, and maxillary is more than the mandible.

The alvusion of the algic tooth often carried out at the urging of the patient leads to move the pain to the maxilla or mandibular bones and most often to the tooth immediately adjacent, which perpetuates the mutilating and useless interventions and transforms the odontalgia in atypical facial algia.

The term phantom tooth partially reflects this situation. Many pulpectomies are also performed as a result of faulty differential diagnoses and lead to the same failures as alvusion (Warnsinck *et alii.*, 2015).

iii. Stomatodynia

It is characterized by a spontaneous and continuous type of burn pain, localized to the buccopharyngeal mucosa, and which is not attributed to any known organic cause.

The painful area is bilateral and symmetrical. It is often associated with dysgeusia and the perception of an abnormal saliva, equated with a xerostomia.

Its frequency is poorly known but has been estimated at less than 0.7% of the adult population. Women are more commonly affected. The period of menopause is the rule, The anxio-depressive context is frequent and the average age is 60 years (Warnsinck *et alii.*, 2015).

iv. Facial arthromyalgia

There are two variants of facial arthromyalgia : musculoaponeurotic pain and painful manifestations accompanying discocondylial disorders. These entities are considered a subset of musculoskeletal dysfunctions. It is a local dull pain aggravated by the use of the mandible with hyperexcitated points frequently associated with the presence of rigid strips in muscle tissue or aponeuroses (Warnsinck *et alii.*, 2015).

v. PDAP specificity

Persistent dento-alveolar pain can be experienced without an identifiable etiology and with a poor response to existing treatments. Confusion over the diagnosis and classification of PDAPs could explain the treatment difficulties and the unfavorable prognosis. Recently, initial steps have been taken to improve the taxonomy and diagnostic criteria of PDAP to improve clinical research and care.

The diagnostic criteria for the PDAP disorder were formulated as an example to be used to model the taxonomic structure of all orofacial pain conditions.

A systematic review determined a frequency of non-dental pain following an endodontic treatment of 3.4%, giving an upper bound estimate (Nixdorf *et alii.*, 2010).

A closer look at the available data restricting her research to articles reporting information consistent with PDAP suggested a frequency of 1.6% after dental treatment involving sensory nerve withdrawal, such as extraction or root canal treatment (Nixdorf *et alii.*, 2011). **(Annex 1)**

Potential risk factors for PDAP following root canal therapy are : prolonged duration of preoperative pain, presence of other chronic pain problems, female gender, and a history of painful treatments in the oro-facial region (Polycarpou *et alii.*, 2005).

The mechanisms that have been proposed for involvement in PDAP are of a psychological or neuropathic nature.

In controlled case studies of psychosocial factors, higher values for various psychological distress measures were reported, which is expected in patients with chronic pain.

Neuropathic factors in patients with PDAP have also been studied in controlled case studies using psycho-physical assessments. In all available data, the threshold for stimulus pain tolerance decreases, and the intensity of pain and duration of supraliminal stimuli increase. The local anesthetic block of peripheral somatic innervation does not significantly reduces pain in half of patients with PDAP.

The diagnosis and treatment of orofacial pain can be complex. Therefore, multidisciplinary diagnosis and treatment are often indicated.

The diagnosis of chronic pain also involves the investigation of psychological factors that may play a role in the chronology of pain, but may also be a consequence.

Patients with persistent orofacial disorders should be examined by a medical team consisting of an oral and maxillofacial surgeon, a neurologist, an anesthetist / pain specialist, a gnathologist dentist, An orofacial physiotherapist and a psychologist or psychiatrist specializing in orofacial pain (Geurts *et alii.*, 2016). **(Annex 2)**

II. Diagnostics and evaluations

1. Diagnosis of neuropathic pain

The diagnostic tool DN4 was validated on the basis of a large French multicentric study in

160 pain patients. The DN4 contains 10 dichotomic items divided into 4 sets of questions.

The first two questions are based on the examination and seek the presence or absence of 7 painful symptoms. The last two questions are based on a simplified clinical examination of the sensitivity in the painful territory.

A score of 1 is assigned to each positive item and a score of 0 to each negative item, the total score being on side 10. The validation study established that a score of at least 4/10 allowed Oriented towards the diagnosis of neuropathic pain, with excellent specificity (89.9%) and sensitivity (82.9%).

The interrogation part of this tool also has a very good diagnostic value and has been validated as a self-questionnaire.

The DN4 has been translated into 25 languages and revalidated in 5 other languages: Spanish, Portuguese, Italian, English and Thai (Bouhassira *et alii.*, 2012). (**Annex 3**)

2. Clinical evaluation of pain

The first step is to review the patient's main complaint and gather all relevant information that can help describe and measure pain. Exo and endo-buccal examinations, clinical tests and diagnostic tests will then be performed.

At the end of these interviews, the patient must be located on axis 1, which reflects the state of the sensory components, and on axis 2, which reflects the psychological, emotional and behavioral state.

The third stage of the consultation will consist of defining with the patient the therapeutic objectives and a reasonable strategy, adapted to its demand and possibilities.

The use of questionnaires facilitates the description of pain by providing patients with lists of pre-established adjectives (Boucher, Pionchon, 2006).

Nominal and ordinal scales are usually used to assess clinical pain as well as the effectiveness of a treatment.

For nominal, quantitative scales, word lists are presented to describe the quality of pain and can be used to discriminate various clinical forms (VAS, scale of six faces, NPRS..).

In ordinal, qualitative scales, multiple categories represent ordered levels of pain. Different

categories can be represented by numbers, verbal designations or images. Each given scale is ideally associated with a single dimension of pain (SVS) .

NPS and NPSI are two self-administered questionnaires with 10 items quantified on numerical scales and a temporal assessment of pain.

The PQAS is a derived version of the NPS, which includes 10 additional items.

The SFMPQ-2 is the most commonly used assessment instrument using a verbal grade scale. Having indicated the location of their pain on a body diagram, patients are presented with a list of words that best represent their painful experience. It has been adapted to a wide variety of clinical situations and has been translated into several languages (Bouhassira *et alii.*, 2012).

The diagnosis of PDAP depends on the elimination of other potential sources of pain. Therefore, the diagnosis of PDAP involves more than traditional dental assessment and intraoral imaging. A series of cases of cerebral MRI taken from a mixed group of chronic facial pain revealed that 7 of the 38 patients imaged had structural lesions striking the 5th cranial nerve. This result prompted the authors of this article to obtain cerebral MRIs on their patients. Between 5 and 10% of PDAP patients have similar structural lesions (Nixdorf *et alii.*, 2011).

III.Treatments

1. Pharmacological treatments

i. The analgesics

The analgesic drugs used correspond to three levels of pain proposed by the WHO :

-non-opiates : paracetamol, non steroidal anti-inflammatory drugs and nefopam

-weak opiates : codeine, dihydrocodeine or tramadol

-strong opiates : morphine

Activation of opioid receptors blocks the transmission of painful messages and stimulates the pain-inhibiting brain centers. Patients receiving opioids may become, paradoxically, more susceptible to pain. It is a loss of analgesic efficacy of opioids, but also an increase in pain

sensitivity, « hyperalgesia induced by opioid ».

Opioids may therefore exhibit inhibitory and facilitating effects on pain (Eschaliier *et alii.*, 2014).

ii. Coanalgesics

Other treatments limit the activity of the immune system (corticosteroids).

The muscle relaxants decrease the medullary reflexes polysynaptic which generate reflex muscle contractions often painful (Tetrazepam, Baclofen).

Ketamine is a blocking agent of the NMDA receptor that modulates pain by interrupting the propagation of the nociceptive signal to the brain, allowing restoration of the physiological balance between pain inhibition and facilitation (Vadivelu *et alii.*, 2016).

iii. The antidepressants

They inhibit the reuptake of serotonin and noradrenaline by neurons, so that the pain-inhibiting brain regions are activated. There is potential for morphine potentiation by antidepressants when combined with endogenous opioids by increasing the number of receptors for morphine. Antidepressants used in neuropathic pain are the molecules of the tricyclic family (amitriptyline) (Chauffour-Ader, Daydé, 2016).

iv. The antiepileptics

Anti-epileptics inhibit the sodium or calcium channels involved in the transmission of the pain message, and reduce neuropathic pain in about one-third of patients. Carbamazepine and valproate are used in trigeminal neuralgia. Clonazepam is used in neuropathic pain (Mico *et alii.* 2006).

v. Local anesthetics

In case of localized neuropathic pain, lidocaine may be used as a plaster. It blocks sodium

channels, limiting the transmission and perception of pain. Ziconotide also blocks some calcium channels, inhibiting the release of neurotransmitters in the spinal cord (Barriot, 2014).

vi. The equimolecular mixture of oxygen and nitrous oxide : MEOPA

MEOPA is considered an adjuvant analgesic due to its properties allowing a reduction of the threshold of the perception of the pain. It causes conscious sedation by acting on the anxiety state of the patient. N₂O would act at the level of the morphine receptors. By releasing opiate mediators, it stimulates the secretion of endomorphins (Dionne *et alii.*, 2002).

vii. Recent advances and rediscoveries

Tapentadol binds to mu opioid receptors and inhibits norepinephrine reuptake, it would be effective in nociceptive and neuropathic pain.

For 20 years, the endogenous cannabinoid system and the properties of certain derivatives have been studied. Thus, a mixture of 9-THC and cannabidiol, in the form of an oral spray, was placed on the market (Eschalier *et alii.*, 2014).

Clonidine is an α_2 -agonist stimulating adrenergic inhibitors of nociception. In chronic pain, it is sometimes used in the bone or as a patch (Bouhassira *et alii.*, 2012).

Capsaicin, an active component of the red pepper and agonist of the TRPV1 receptor, has been available for several years as a low-dose cream and patch in the treatment of neuropathies. Capsaicin in high doses is a new form of patch. Its effectiveness has been proven in the treatment of neuropathic pain. Once applied to the skin, capsaicin causes an increase in sensitivity to nociceptive stimuli, followed by a period of reduced sensitivity and lasting desensitization after repeated applications (Lakloul, Baranidharan, 2016).

Extracted from the pineapple stem, bromelain is one of the remedies with multiple properties : anti-inflammatory, cicatrizing agent,... Since the end of the 20th century, his use and the scientific studies have considerably intensified (Rathnavelu *et alii.*, 2016). **(Annex 4)**

2. Non-pharmacological treatments

The biomedical approach is often insufficient to help patients maintain an "acceptable" quality of life. A so-called bio-psychosocial approach is needed (Vanhaudenhuyse *et alii.*, 2014).

i. Bio-psychosocial therapy

By definition, the bio-psychosocial model includes a biological factor with pharmacological treatments, a psychological component that explores the cognitive mechanisms used to "manage" pain and the socio-occupational factor that takes into account the disability caused by pain. This global approach makes it possible to adapt the care to each patient and to encourage him to use his personal resources (Vanhaudenhuyse *et alii.*, 2014).

ii. Cognitive Behavior Therapy

CBT is a part of an experimental scientific approach based on theories of learning new behaviors, based on the development of more appropriate thoughts.

-The cognitive aspect corresponds to what happens in the brain of the person, that is to say, the way in which it reflects on things and how it represents them.

-The behavioral aspect covers what the person actually does in her everyday life.

Motivational interviewing is a directive, patient-centered method, the goal of which is to increase the motivation for change by exploring and resolving the ambivalence associated with change. Medical consultation in general and the field of chronic pain in particular (Berquin, Grisart, 2016).

Relaxation covers an important set of methods and techniques whose main purpose is to achieve relaxation of muscle tone and psyche by concentrating on body sensations and respiratory work (Thibault, Fournival, 2012).

Biofeedback is based on the use of different physiological measuring devices during a relaxation session so that the patient, in his or her daily life, can reproduce the attitudes and behaviors that he / she has identified as useful for the relief of his or her pain (Chauffour-

Ader, Daydé, 2016).

Visual feedback and in particular mirror therapy have been widely developed for the treatment of certain neuropathic pain, the mechanisms of which involve in particular changes in cortical plasticity, in particular phantom pain (Bouhassira *et alii.*, 2012). **(Annex 5)**

In a study published by Nature in June 2014, American scientists succeeded in relocating memories in the memory of rats after erasing them. This experiment reveals the same mechanisms involved in cerebral plasticity of pain and memory. **(Annex 6)**

Psychotherapy is of tremendous importance in the treatment of neuropathic pain, as difficulties in coping with pain often lead to depressive and anxiety disorders (Bouhassira *et alii.*, 2012). **(Annex 7)**

For example, for phantom pain after extraction, the psychological explanation would be that the person did not mourn the situation that the tooth represents. The problem that motivated the extraction of the tooth is still active in the unconscious (Vereeck, 2004).

Hypnosis is very often used in addition to other techniques to relieve acute or chronic pain in adults or children (Bouhassira *et alii.*, 2012). **(Annex 8)**

Hypnosis is defined as "a modified state of transient and artificial consciousness caused by the suggestion of another person". Its use in the relief of pain was described in 1843, when a dentist, J. Braid, used it in anesthesia.

The autogenous training of Schultz is a self-hypnosis based on a two-level work. The first is based on a series of six mental exercises of concentration, based on precise verbal suggestions validated with a therapist and the second allows a psychic work more developed from the state of relaxation obtained by the patient and from positive mental representations (Chauffour-Ader, Daydé, 2016).

Some artistic practices have demonstrated their clinical effectiveness for the treatment of painful patients: music, painting. The mechanism of action is twofold: it distracts and liberates the negative emotions associated with pain (Thibault, Fournival, 2012).

iii. The physical and physiological methods

Cryotherapy, thermotherapy, Scottish bath and comfort massages act on inflammatory pain by modulating vasodilation and / or vasoconstriction, which helps drain the edema responsible for pain. Vasodilatation caused by warmth and massages promotes muscular and psychic relaxation, thus increasing the tolerance threshold for pain. These mechanisms are related to an activation of heat receptors that block the effect of chemical messengers responsible for pain (Thibault, Fournival, 2012).

The Whole body cryotherapy is now accessible to the painful patient. In terms of pain management, the place of the physiotherapist in the care team is important. It contributes to improving the quality of life of patients (Chauffour-Ader, Daydé, 2016).

Some patients with chronic refractory pain may be relieved by neurosurgical techniques known as lesional or neuromodulation, when other therapeutic means have failed (Treede, 2016).

iv. Neurostimulation / Neuromodulation

We distinguish non invasive techniques, TENS and rTMS, invasive techniques, medullary, cortical, deep cerebral and peripheral nervous stimulation. The therapeutic principle of these methods is to stimulate non-nociceptive inhibitory pathways (Nizard, *et alii.*, 2014).

The theory of gate control described by Melzack and Wall explains the clinical observations of pain in most injuries and diseases. The caudalis nucleus acts as a « gate » for the sensory input of the trigeminal nerve, so the pain can be altered in the caudal nucleus by inhibitory or stimulatory influences and modify the sensations reaching the cortex (Treede, 2016).

(Annex 9)

On the basis of studies on the neurochemical mechanisms involved in pain control, the possibility of intervening directly on targets (stimulations of the periventricular and periaqueductal grey matter) has been identified with the aim of increasing the secretion of endomorphinic systems and Serotonergic drugs. Then, intrathecal morphine therapy was developed to inject morphine beyond the blood-brain barrier, close to opiate receptors. The success of analgesic surgery depends on the anatomical and physiological recognition : pain by excess of nociceptive affections and / or pain by default of the inhibitory control

(Sindou *et alii.*, 2015).

v. Neurosurgery

Neurosurgical treatment is exclusively for chronic pain resistant to drug therapy and to biopsychosocial management. The lesional techniques target in a hyperselective manner the nociceptive routes, allowing to relieve certain pain, limited topography, cancerous or in selected cases of pain of neurological origin (Fontaine *et alii.*, 2015).

a. Direct nervous anastomosis

Cranial nerve lesions are used for the treatment of essential neuralgias, especially trigeminal but also glossopharyngeal, either by microsurgical section in the bridgeocerebellar angle or by percutaneous thermocoagulation by means of an electrode introduced under radiological control by the foramen ovale for the nerve V and foramen jugularis for the nerves IX-X.

An alternative is represented by the group of operations on the descending trigeminal tract or the spinal nucleus by stereotactic or direct approach or by a percutaneous pathway guided by computed tomography.

Popularized as the first and very important level of modulation of sensitivity and nociception by gate control theory, DREZ in the caudalis nucleus was considered a potential target for the treatment of certain pain.

Compression by microballoon can be used in case of neuralgia V1.

Microsurgical vascular decompression aims to resolve the vasculo-nervous conflict responsible for facial neuralgia. The success rate of this technique is over 80%. Radiosurgery consists of single-dose stereotactic focal irradiation of the trigeminal nerve, which is homolateral to pain (Fontaine *et alii.*, 2015).

b. Graffes

Neurosurgery in the maxillofacial region is confined to the trigeminal and facial nerves. The most common cause of the trigeminal nerve injury is dental extraction, especially that of the

third mandibular molar, which may affect the lower alveolar and lingual nerves. It is recognized that the best results will be obtained with a direct anastomosis of the two ends of the nerve to be repaired. However, if there is a gap between the two ends, a nerve filling graft will be required. The two nerves most commonly used to graft the trigeminal nerve are the sural nerve and the superior atrial nerve. Other ducts have been used for nerve transplants. These include autologous vein grafts (Jones, 2010).

It seems that a venous graft can form a physiological conduit for nerve regeneration (Pogrel, Maghen 2001). (**Annex 10**)

The use of various allografts such as Gore Tex, Neurotube (PGA) are also an alternative for nerve grafts. These ducts can be filled with nerve growth factors (Jones, 2010).

PART 4 : DISCUSSION / CONCLUSION

From a biological and evolutionary point of view, pain is information that allows consciousness to experience the state of its body in order to respond to it.

In recent years, it has been realized that specialized centers for pain management, consisting of multidisciplinary teams, are needed.

The treatment of pain must be a « tailor-made » treatment chosen by the doctor in consultation with the patient, to alter the patient's quality of life as little as possible.

Pain is said to be the cause of almost two thirds of medical consultations, which is why it is the subject of numerous studies, both fundamental and clinical.

This research is particularly necessary to understand more precisely the mechanisms involved in pain and thus to enable the development of new treatments.

Chronicity is not treated in an emergency, the urgency of getting better goes through a slow construction.

Non-pharmacological therapies have a significant interest in neuropathic pain and may be offered alone or in combination with drug therapies. Studies remain necessary to better evaluate the usefulness of these techniques, in particular by comparing them with pharmacological treatments.

In all cases, recourse to rehabilitation and psychotherapy is often necessary and is an essential multidisciplinary approach to chronic pain.

PART 5 : BIBLIOGRAPHY

A

Abdeshahi, SK. *et alii.* (2013). Effect of hypnosis on induction of local anaesthesia, pain perception, control of haemorrhage and anxiety during extraction of third molars : a case-control study, *Journal of cranio-maxillo-facial surgery*, volume 41/ issue 4/ monthly/ June, pp. 310–315

B

Barriot, P. (2014). Les paradoxes de l'anesthésie, *Cerveau & Psycho*, n°17/ special edition/ February-April, pp. 76-80

Berquin, A., Grisart, J. (2016). *Les défis de la douleur chronique*, Belgique, Mardaga

Boucher, Y., Pionchon, P. (2006). *Douleurs orofaciales : diagnostic et traitement*, France, CdP

Bouhassira, D. *et alii.* (2012). *Douleurs neuropathiques*, France, Arnette

C

Callaway, E. (2014). Flashes of light show how memories are made. [on line]. Disponible on : <<http://www.nature.com/news/flashes-of-light-show-how-memories-are-made-1.15330>> [consulted the 24/10/2016]

Chauffour-Ader C., Daydé MC. (2016). *Comprendre et soulager la douleur*, France, Lamarre

Cole, J. *et alii.* (2009). Exploratory findings with virtual reality for phantom limb pain ; from stump motion to agency and analgesia, *Disability and Rehabilitation*, volume 31/ issue 10, pp. 846-854

D

Delzangles, B. (2015). *Hypnose et odontologie osez le voyage...*, Belgique, Satas-Le Germe

Dionne, RA. *et alii.* (2002). *Management of pain and anxiety in the dental office*, Philadelphia, Saunders

E

Eschalier, A. *et alii.* (2014). Les médicaments antidouleurs, *Cerveau & Psycho*, n°17/ special edition/ February-April, pp. 64-68

PERSISTENT DENTO ALVEOLAR PAIN DISORDER : DIAGNOSTIC AND TREATMENT

F

Fontaine, D. *et alii.* (2015). Neurosurgical treatment of chronic pain, *Neurochirurgie*, volume 61/ issue 1/ monthly/ February, pp. 22-29

G

Geurts, JW., Haumann, J., van Kleef, M. (2016). Multidisciplinary treatment of orofacial pain, *Nederlands Tijdschrift voor Tandheelkunde*, n°123/ monthly/ November, pp. 547-551

Golezar, S. (2016). Ananas comosus Effect on Perineal Pain and Wound Healing After Episiotomy : A Randomized Double-Blind Placebo-Controlled Clinical Trial, *Iran Red Crescent Medical Journal*, volume 18/ issue 3/ monthly/ March, e21019

Guenther, K. (2016). « It's All Done With Mirrors » : V.S. Ramachandran and the Material Culture of Phantom Limb Research, *Medical History*, volume 60/ issue 3/ monthly/ July, pp. 342-358

I

IASP [on line] disponible on : <<http://www.iasp-pain.org/>> [consulted the 02/10/2016]

J

Jones, RH. (2010). Repair of the trigeminal nerve : a review, *Australian Dental Journal*, volume 55/ issue 2/ monthly/ June, pp. 112-119

K

Katz, J., Rosenbloom, BN. (2015). The golden anniversary of Melzack and Wall's gate control theory of pain : Celebrating 50 years of pain research and management, *Pain research and Management*, bimonthly/ November-December, volume 20/ issue 6, pp. 285-286

L

Lakloul, M., Baranidharan, G. (2016). Profile of the capsaicin 8% patch for the management of neuropathic pain associated with postherpetic neuralgia: safety, efficacy, and patient acceptability, *Dove Press*, volume 10, pp. 1913-1918

Laurent, B., Pickering, G. (2014). La mémoire de la douleur, *Cerveau & Psycho*, n°17/ special edition/ February-April, pp. 34-39

PERSISTENT DENTO ALVEOLAR PAIN DISORDER : DIAGNOSTIC AND TREATMENT

M

Mico, J. *et alii.* (2006). Antidepressants and pain, *Trends in Pharmacological Sciences*, volume 27, pp. 348-354

N

Nixdorf, D. *et alii.* (2011). Persistent Dento-Alveolar Pain Disorder (PDAP) : Working towards a Better Understanding, *Reviews in Pain*, volume 5/ issue 4, pp.18-27

Nixdorf, D. *et alii.* (2012). Classifying orofacial pains: a new proposal of taxonomy based on ontology, *Journal of Oral Rehabilitation*, volume 39/ issue 3/ monthly/ March, pp. 161-169

Nizard, J. *et alii.* (2014). Calmer la douleur en stimuler les neurones, *Cerveau & Psycho*, n°17/ special edition/ February-April, pp. 70-75

P

Pain In Europe [on line] disponible on : <<http://www.intercomsante57.fr/html/profsante/pdf/Douleurs-chroniques.pdf>> [consulted the 09/10/2016]

painSTORY [on line] disponible on : <<http://www.painstory.org/fr>> [consulted the 09/10/2016]

Pitta, MC. *et alii.* (2001). Use of Gore Tex tubing as a conduit for inferior alveolar and lingual nerve repair: experience with 6 cases, *Journal of Oral and Maxillofacial surgery*, volume 59/ issue 5/ monthly/ May, pp. 493-496

Pogrel, MA., Maghen, A. (2001). The use of autogenous vein grafts for inferior alveolar and lingual nerve reconstruction, *Journal of Oral and Maxillofacial surgery*, volume 59/ issue 9/ monthly/ September, pp. 985-988

Polycarpou, N. *et alii.* (2005). Prevalence of persistent pain after endodontic treatment and factors affecting its occurrence in cases with complete radiographic healing, *International Endodontic Journal*, volume 38/ issue 3/ monthly/ March, pp. 169-178

Purves, D. *et alii.* (2015). *Neurosciences*, France, De Boeck Supérieur

R

Ramachandran, VS., Altschuler, EL. (2009). The use of visual feedback, in particular mirror visual feedback, in restoring brain function, V. S. Ramachandran, *Brain a Journal of Neurology*, volume 132/ issue 7/ monthly/ July, pp.1693-1710

PERSISTENT DENTO ALVEOLAR PAIN DISORDER : DIAGNOSTIC AND TREATMENT

Rathnavelu, V. *et alii.* (2016). Potential role of bromelain in clinical and therapeutic applications, *Biomedical Reports*, volume 5/ issue 3/ monthly/ September, pp. 283-288

Rostaing, S. *et alii.* (2010). La Douleur, des recommandations à la pratique, *Institut UPSA de la douleur*, n°9/ monthly/ February

S

Schrijvers, D. (2007). Pain control in cancer : Recent findings and trends. [on line]. Disponible on : < https://www.researchgate.net/publication/6205980_Pain_control_in_cancer_Recent_findings_and_trends> [consulted the 21/02/2017]

Sindou, M. *et alii.* (2015). Traitements neurochirurgicaux de la douleur chronique, *Douleur et analgésie*, volume 28/ issue 3/ monthly/ September, pp. 131-138

T

Thibault, P., Fournival, N. (2012). *Moyens non pharmacologiques de prise en charge de la douleur*, France, Lamarre

Treede, RD. (2016). Gain control mechanisms in the nociceptive system, *Pain*, volume 157/ issue 6/ monthly/ June, pp. 1199-1204

V

Vadivelu, N. *et alii.* (2016). Role of ketamine for analgesia in adults and children, *Journal of Anaesthesiology Clinical Pharmacology*, volume 32/ issue 3, pp. 298-306

Vanhaudenhuyse, A. *et alii.* (2014). Neurophysiology of hypnosis, *Clinical Neurophysiology*, volume 44/ issue 4/ monthly/ October, pp. 343-353

Vereeck, E. (2004). *Dictionnaire du langage de vos dents*, France, Luigi Castelli

W

Warnsinck, CJ. *et alii.* (2015). Persistent dento-alveolar pain disorder (PDAP), *Nederlands Tijdschrift voor Tandheelkunde*, n°122/ monthly/ February, pp. 95-100

Wickelgren, I. (2011). La sensibilité à la douleur, *Cerveau & Psycho*, n°44/ bimonthly/ March-April, pp. 64-70

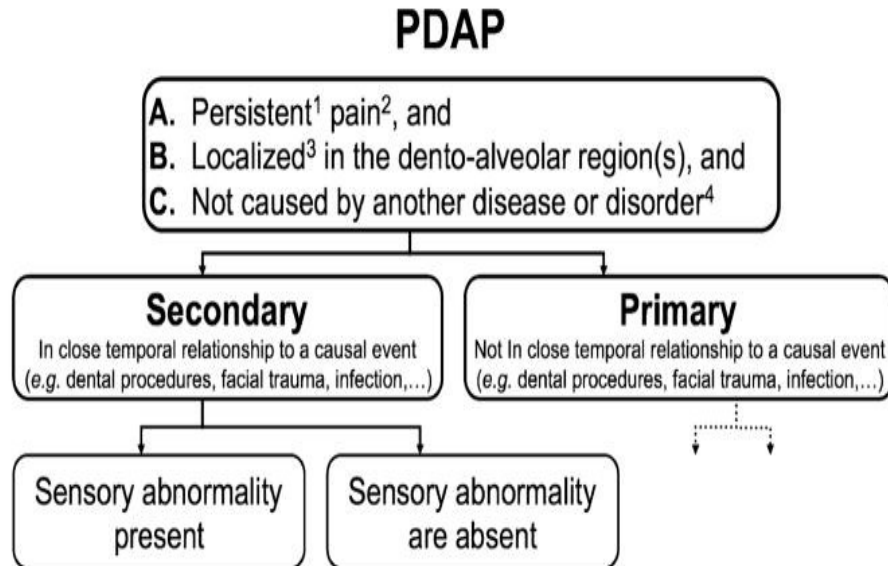
PART 6 : ANNEX

Annex 1 : Prevalence data abstracted from available articles that clinically confirmed diagnosis of PDAP

Author	Year published	Total sample enrolled	Follow up rate (%)	Clinical cases of PDAP	Frequency of PDAP (%)
Marbach <i>et alii.</i>	1982	732	70	8	1,1
Campbell <i>et alii.</i>	1990	118	100	6	5,1
Pollmann	1993	2620	100	25	1
Jacobs <i>et alii.</i>	2002	500	35	8	1,6
Polycarpou <i>et alii.</i>	2005	400	44	21	5,2

(Nixdorf *et alii.*, 2011)

Annex 2 : Diagnostic Criteria for PDAP



Criteria :

1 persistent meaning pain present at least 8 h per day \geq 15 days or more per month for \geq 3 months during

2 pain is defined as per IASP criteria (includes dysesthesia)

3 localised meaning the maximum pain defined within an anatomical area

4 extent of evaluation non-specified (dental, neurological examination +/-) imaging, such as intra-oral, CT and / or MRI)

(Nixdorf *et alii.*, 2012)

Annex 3 : DN4 Questionnaire

Please complete this questionnaire by ticking one answer for each item in the four questions below:

INTERVIEW OF THE PATIENT

Question 1: Does the pain have one or more of the following characteristics?

	Yes	No
1 - Burning	<input type="checkbox"/>	<input type="checkbox"/>
2 - Painful cold	<input type="checkbox"/>	<input type="checkbox"/>
3 - Electric shocks	<input type="checkbox"/>	<input type="checkbox"/>

Question 2: Is the pain associated with one or more of the following symptoms in the same area?

	Yes	No
4 - Tingling	<input type="checkbox"/>	<input type="checkbox"/>
5 - Pins and needles	<input type="checkbox"/>	<input type="checkbox"/>
6 - Numbness	<input type="checkbox"/>	<input type="checkbox"/>
7 - Itching	<input type="checkbox"/>	<input type="checkbox"/>

EXAMINATION OF THE PATIENT

Question 3: Is the pain located in an area where the physical examination may reveal one or more of the following characteristics?

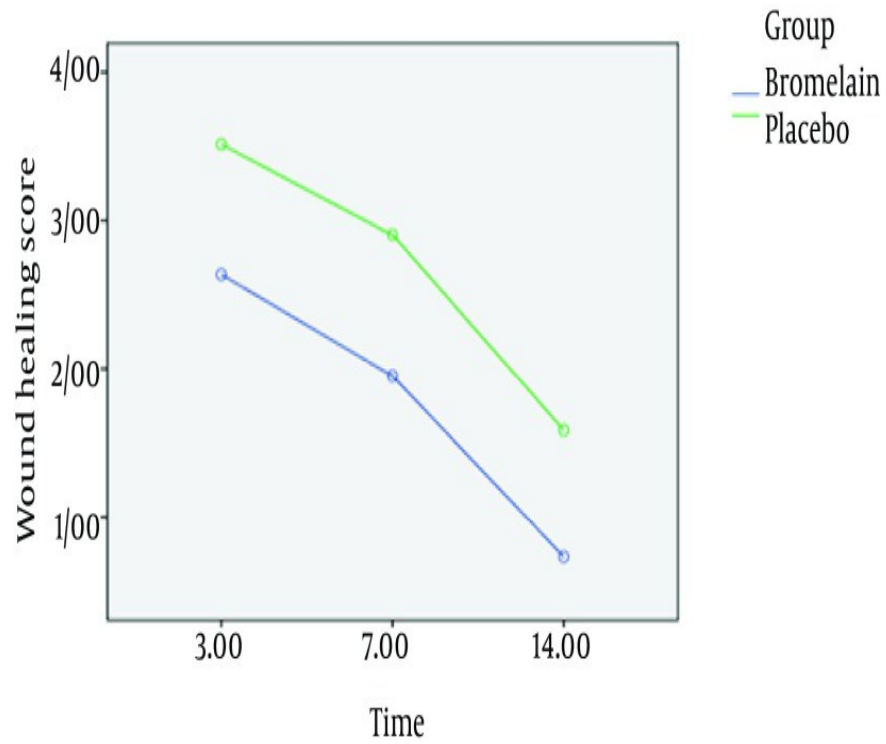
	Yes	No
8 - Hypoesthesia to touch	<input type="checkbox"/>	<input type="checkbox"/>
9 - Hypoesthesia to prick	<input type="checkbox"/>	<input type="checkbox"/>

Question 4: In the painful area, can the pain be caused or increased by:

	Yes	No
10 - Brushing	<input type="checkbox"/>	<input type="checkbox"/>


(Schrijvers, 2007)

Annex 4 : Mean Wound Healing Score for the Two Study Groups in 14-Day Period



(Golezar, 2016)

Annex 5 : Ramachandran's mirror box



The "mirror box" consists of a 2×2 mirror vertically raised sagittally in the middle of a rectangular box. The top and front sides of the box are removed. The patient then places his left ghost member on the left side of the mirror and his hand intact to his right. He then looks at the shiny side of the mirror, the reflection of the right hand intact, so that his reflection seems superimposed, thus creating the illusion that the ghost member has been resurrected. While looking in the mirror, he sends motor commands to both hands to make symmetrical movements and he gets the visual impression that his ghost hand "obeys" his command (Guenther, 2016).

A new variant of the Ramachandran method captures motion data directly from a patient's stump and then transforms it into an avatar-driven virtual action in a virtual reality environment (Cole *et alii.*, 2009).

The beneficial effects of the visual feedback mirror on phantom pain have been confirmed in several studies (McLachlan *et al.*, 2004, Chan *et al.*, 2007, Sumitani *et al.*). The most recent was conducted by Tsao and colleagues (Chan *et al.*, 2007) who tested the visual feedback mirror on 22 patients, 18 completing their study. After 4 weeks, the mean pain level of the visual analog scale (VAS) fell from about 30/100 initially to 5/100 in the mirror therapy group (Ramachandran, Altschuler, 2009).

Annex 6 : Flashes of light show how memories are made

The experiments confirmed a long-standing theory on how memories are made and stored in the brain. The researchers created and erased painful associations in the brain of rats using light, demonstrating that the strengthening and weakening of connections between neurons is the basis of memory.

In the 1960s and 1970s, Norwegian researchers noticed a particular property of brain cells. Repeated transmission of a burst of electricity to a neuron in a region of the brain, the hippocampus, seemed to stimulate the ability of the cell to interact with a neighboring neuron. These communications occur through tiny gaps called synapses. The process was called PLT, and neuroscientists suspected that this process was the physical basis of memory.

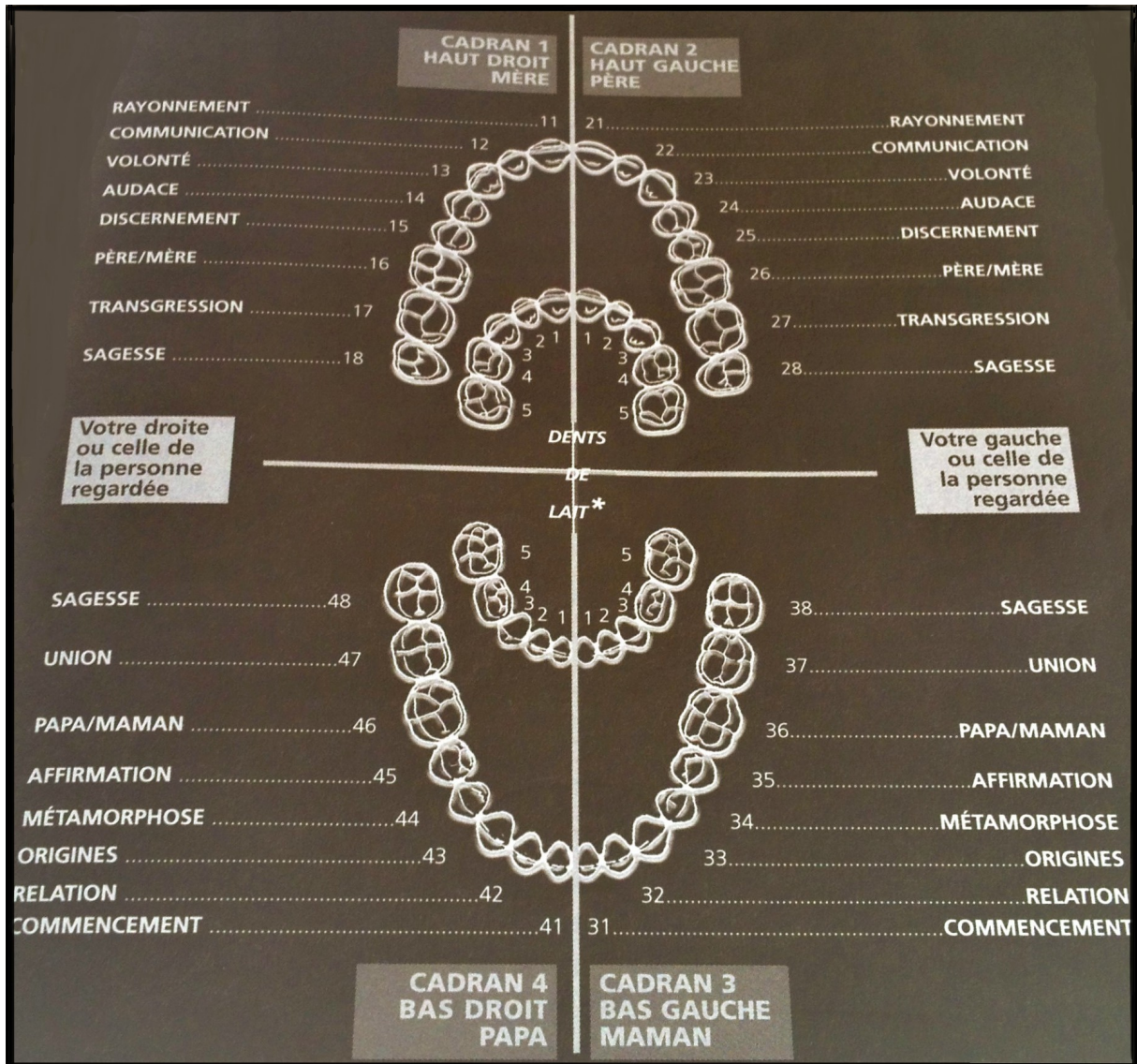
The hippocampus is the seat of long-term memories and the enduring nature of the PLT could be stored in a neural circuit. A team led by Roberto Malinow, a neuroscientist at the University of California, San Diego, has turned to a technique that uses light to activate neurons. The researchers inserted a gene that produces a photosensitive protein into a virus, and then this virus is injected into the rat brain cells they wanted to study. Once the gene has been translated into protein, researchers have been able to activate this protein with a pulse of blue light, delivered by an optical fiber implanted in the rat brain.

Thanks to the light generated by the fiber, they were able to manipulate the synapses, the contact between two neurons, causing an electrical discharge in the foot of the rat. The latter associates the fear of the discharge with the impulse of light. But when synapses were stimulated at a low frequency, memories were weakened, the researchers note. A high frequency pulse caused the opposite effect: the rats were afraid.

Synapses of neurons have shown molecular changes that are a feature of PLT. But to prove that PLT was involved in the actual formation of memory, the researchers then undertook to erase the association and bring it back by strengthening the connection using PLT. This, too, could be accomplished with the light that activated the neurons that stored memory.

Rats that have been exposed to a sequence of light pulses are no longer curled up for fear of anticipating the pain after being simulated. The fear could be re-implanted in their brains by delivering known light pulses to create the P LT, then erased and brought back (Callaway, 2014).

Annex 7 : Scheme of symbolic meaning of the teeth



(Vereeck, 2004)

Annex 8 : Effect of hypnosis on induction of local anaesthesia, pain perception, control of haemorrhage and anxiety during extraction of third molars : a case-control study

The results of the study « Effect of hypnosis on induction of pain perception, control of haemorrhage and anxiety during extraction of third molars: a case-control study », of June 2013, showed that hypnosis can reduce anxiety, hemorrhage and pain.

In this case-control study, 24 female and male underwent an extraction of the third molars. A total of 48 third molars were extracted. Patients were used as their own controls, the third molars on one side being removed under hypnosis and on the opposite side under local anesthetic.

The intensity of pain in both groups at 5 and 12 postoperative hours showed significant differences. The pain was evaluated using VAS.

In the hypnosis group, 10 patients (41.7%) took painkillers.

In the local anesthesia group, 22 patients (91.7%) took analgesics.

Patients reported less pain when they were under hypnosis.

(Abdeshahi *et alii.*, 2013)

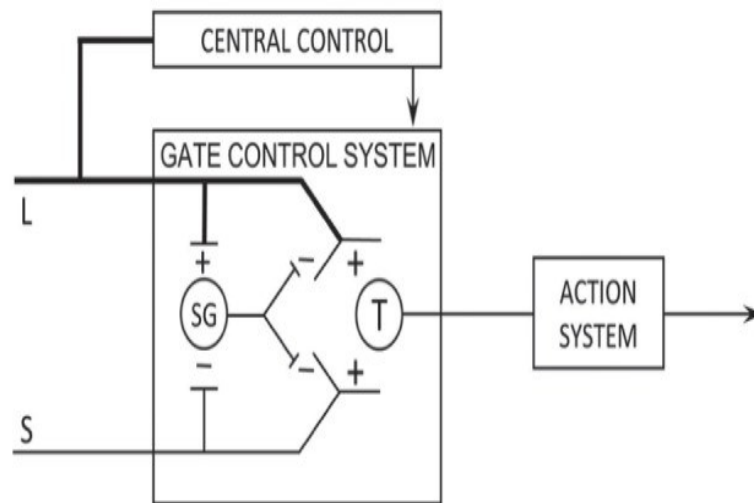
Annex 9 : Melzack and Wall's gate control theory of pain

Melzack and Wall demonstrated in 1965 the existence of a gate that modulates the nerve impulses: the sensitivity of the nociceptive system can be diminished or increased at the peripheral, spinal and supraspinal levels. The input of the sensory organs of the face is subjected to various conscious and subconscious stimuli which can modify this sensory input.

This work led to the advent of electroanalgesic methods by stimulation of primary afferent pathways, either at the level of the peripheral nerves (Wall and Sweet) or at the level of the posterior cords. At the same time, Mazars, relying on Head's and Holmes' conceptions that the pathways of lemniscal sensitivity would control the activity of the pathways of extralemniscal (ie, painful) sensation at the thalamic level, Of intermittent thalamic analgesic stimulation by implantation of electrodes at the level of the ventro-posterolateral nucleus (VPL), relay of the lemniscal somaesthetic pathways and a true "filter" of painful affections.

More recently, the technique of stimulation of the motor cerebral cortex with an analgesic aim was born. This technique was introduced by Tsubokawa in 1991 after the empirical observation that stimulation of the cortex in front of the central groove of Rolando had analgesic effects (Sindou M. et al., 2015).

The respective indications of these different techniques depend on several factors: the physiological age of the patient, the topography of the pain, the history of surgical treatment, the severity of the pain, the patient's choice and the availability of each technique in the Neurosurgical center that takes care of it.



Scheme of the gate control theory proposed by Melzack and Wall, showing how the mechanism of passage in the dorsal horn of the spine modulates the transmission of the nerve impulses of the fibers afferent to the cells of transmission: «T» of the spinal cord .

The locking mechanism is affected by the relative activity of the large fibers: "L" and small: "S" diameter, the former inhibiting the transmission (closing the door) and the second facilitating transmission (opening the door). The spinal passage: "SG" is also modulated by nerve impulses descending from the brain: "central control".

(Katz, Rosenbloom, 2015)

Annex 10 : Use of Gore-Tex Tubing as a Conduit for Inferior Alveolar and Lingual Nerve Repair: Experience With 6 Cases

Six patients (5 female and 1 male) with painful dysesthesia secondary to injuries of the IAN (n = 3) or LN (n = 3) underwent surgical exploration and resection of pathologic tissue. Reconstruction of the resultant continuity defects was performed using 3-mm diameter GT tubing sutured to the epineurium of the proximal and distal nerve trunks. Nerve reconstruction was performed an average of 20 months after injury (range, 4 to 48 months).

Patients were tested before and after surgery with the following tests: subjective pain level using an analogue scale, sharp stimulus, touch, cold sensation, directional sense, and 2-point discrimination.

Four patients reported no change in subjective pain level, and 2 patients had minimal decrease in pain. Two patients reported some sensation to sharp stimulus, and 1 patient was hypersensitive. Three patients responded to touch, and 3 had no response. Four patients had no response to cold sensation, and 2 had a delayed response. Only 1 patient could detect brushstroke direction. Three patients had no response to 2-point discrimination, and 3 responded at greater than 20 mm.

Use of GT tubing in this group of patients produced poor clinical outcomes and is not recommended for nerve reconstruction of IAN and LN continuity defects.

(Pitta *et alii.*, 2001)

Part 7 : COPYRIGHTS

Annex 1 : Prevalence data abstracted from available articles that clinically confirmed diagnosis of PDAP

Persistent Dento-Alveolar Pain Disorder (PDAP) : Working towards a Better Understanding
 Donald Nixdorf, DDS MS* and Estephan Moana-Filho,
 Copyright © 2011 British Pain Society

Annex 2 : Diagnostic Criteria for PDAP

JOHN WILEY AND SONS LICENSE TERMS AND CONDITIONS

Mar 23, 2017

This Agreement between Florence Orlik ("You") and John Wiley and Sons ("John Wiley and Sons") consists of your license details and the terms and conditions provided by John Wiley and Sons and Copyright Clearance Center.

License Number	4074860466764		
License date			
Licensed Content Publisher	John Wiley and Sons		
Licensed Content Publication	Journal of Oral Rehabilitation		
Licensed Content Title	Classifying orofacial pains: a new proposal of taxonomy based on ontology		
Licensed Content Author	D. R. NIXDORF, M. T. DRANGSHOLT, D. A. ETTLIN, C. GAUL, R. De LEEUW, P. SVENSSON, J. M. ZAKRZEWSKA, A. DE LAAT, W. CEUSTERS		
Licensed Content Date	Aug 18, 2011		
Licensed Content Pages	9		
Type of use	Dissertation/Thesis		
Requestor type	University/Academic		
Format	Print and electronic		
Portion	Figure/table		
Number of figures/tables	1		
Original Wiley figure/table number(s)	figure 2		
Will you be translating?	No		
Title of your thesis / dissertation	/ PERSISTENT DENTO ALVEOLAR PAIN DISORDER : DIAGNOSTIC AND TREATMENT		
Expected completion date	May 2017		
Expected size (number of pages)	40		
	Florence		Orlik
	115	av	victor hugo
Requestor Location	paris, France Attn: Florence Orlik		75116
Publisher Tax ID	EU826007151		
Billing Type	Invoice		

Annex 3 : Questionary DN4

Pain control in cancer : Recent findings and trends (PDF Download Available). Available from: https://www.researchgate.net/publication/6205980_Pain_control_in_cancer_Recent_findings_and_trends
Copyright © 2007 Annals of Oncology

Annex 4 : Mean Wound Healing Score for the Two Study Groups in 14-Day Period

Samira Golezar Ananas comosus Effect on Perineal Pain and Wound Healing After Episiotomy : A Randomized Double-Blind Placebo-Controlled Clinical Trial

Copyright © 2016, Iranian Red Crescent Medical Journal.

This is an open-access article distributed under the terms of the Creative Commons Attribution-NonCommercial 4.0 International License (<http://creativecommons.org/licenses/by-nc/4.0/>) which permits copy and redistribute the material just in noncommercial usages, provided the original work is properly cited.

Annex 5 : Ramachandran's mirror box

'It's All Done With Mirrors': V.S. Ramachandran and the Material Culture of Phantom Limb Research
Katja Guenther*Copyright © The Author 2016

Annex 7 : Scheme of symbolic meaning of the teeth

Editions Luigi Castelli : Dictionnaire du langage de vos dents, E. Vereeck 2004

Bonsoir,

Ok, pas de problème.

Cordialement

LC

Le 22 mars 17 à 15:18

Annex 9 : Melzack and Wall's gate control theory of pain

Katz, J., Rosenbloom, BN. (2015). The golden anniversary of Melzack and Wall's gate control theory of pain: Celebrating 50 years of pain research and management

Copyright © 2015, Pulsus Group Inc. All rights reserved

This open-access article is distributed under the terms of the Creative Commons Attribution Non-Commercial License (CC BY-NC) (<http://creativecommons.org/licenses/by-nc/4.0/>), which permits reuse, distribution and reproduction of the article, provided that the original work is properly cited and the reuse is restricted to noncommercial purposes. For commercial reuse, contact moc.suslup@troppus