

Roger Nicolas Bou Serhal

Peri-Implantitis: Etiology, Risk Factors and Treatment Concepts

Universidade Fernando Pessoa

Faculdade de Ciências da Saúde

Porto, 2018

Roger Nicolas Bou Serhal

Peri-Implantitis: Etiology, Risk Factors and Treatment Concepts

Universidade Fernando Pessoa

Faculdade de Ciências da Saúde

Porto, 2018

Roger Nicolas Bou Serhal

Peri-Implantitis: Etiology, Risk Factors and Treatment Concepts

Dissertação apresentada à Universidade
Fernando Pessoa como parte dos requisitos para
obtenção do grau de Mestre em Medicina
Dentária

ACKNOWLEDGMENTS :

« *What You Are Is Where You Where When.....AGAIN* » Morris Massey.

« *Whatever you thought,think again.* » Willem Meiners.

« Ils le peuvent parce qu'ils pensent qu'ils le peuvent. » Virgile.

A mon pere Nicolas et ma mere Amal qui sans rien n'aurait ete fait

A mon frere Toto qui est mon soutien

RESUMO

Objetivo : A Peri-implantitis é uma doença inflamatória que afeta os tecidos moles e duros que cercam um implante em função. A eliminação do biofilme estabelecido e a descontaminação da superfície do implante é o objetivo principal no tratamento da peri-implantite. **Métodos:** Algumas técnicas cirúrgicas podem ser necessárias para nos proporcionar um acesso adequado para desgranular eficazmente os tecidos inflamados, bem como para descontaminar e, se indicado, modificar a superfície do implante. Antes da utilização de técnicas cirúrgicas, a terapia não cirúrgica e o reforço da higiene bucal devem ser realizados. **Resultados:** Como em qualquer doença, a prevenção é a melhor forma de tratamento e a peri-implantite não é exceção. O diagnóstico precoce da doença peri-implantar pode ajudar a controlar a progressão e permite a sua resolução por meios não cirúrgicos no caso de mucosite peri-implante. **Conclusão:** As doenças peri-implantes são doenças importantes como resultado de sua alta prevalência e da falta de um modo padrão de terapia. Um estudo completo dos fatores de risco locais e sistêmicos do paciente é importante antes de qualquer tratamento com implante.

Palavra-chave: Osseointegração, sobrecarga oclusal, excesso de cimento, sangramento na sondagem, superfície descontaminação, terapia regenerativa.

ABSTRACT

Aim: Peri-implantitis is an inflammatory disease affecting soft and hard tissues surrounding a functional implant. The elimination of the established biofilm and decontamination of the implant surface are the main objectives in the treatment of peri-implantitis. **Methods :** Surgical techniques may be necessary to provide adequate access to degranulate the inflamed tissues effectively as well as to decontaminate and, if indicated, modify the implant surface. Before surgical techniques are employed, nonsurgical therapy and reinforcement of the oral hygiene should be performed. **Results:** As with every disease, prevention is the best treatment. Early peri-implant disease diagnosis can help in controlling the progression and its resolution by non-surgical means in the case of peri-implant mucositis. **Conclusion:** Peri-implant diseases are important disease entities because of their high prevalence and the lack of a standard mode of therapy. Thorough study of the patient's local and systemic risk factors is important before any implant treatment.

Key-words: Osseointegration, occlusal overload, excess of cement, bleeding on probing, surface decontamination, regenerative therapy.

INDEX

ACKNOWLEDGMENTS :	v
RESUMO	vi
ABSTRACT	vii
INDEX OF FIGURES	ix
TABLE INDEX	x
INDEX OF ABBREVIATION	xi
I. INTRODUCTION	1
1. Definitions	1
II. RESULTS	2
1. ANATOMIC AND HISTOLOGICAL CONSIDERATIONS	2
i. Peri-Implant mucosa	2
ii. Attachment apparatus	2
2. PHYSIOLOGIC CONSIDERATIONS	2
i. Osseointegration	2
3. ETIOLOGY AND RISK FACTORS OF MARGINAL BONE LOSS	2
ii. Periodontal tissues	3
iii. Implant properties	4
iv. Surgery and implant placement	5
v. Prosthetic aspects	6
vi. Systemic factors	7
4. DIAGNOSIS	8
i. Clinical diagnosis	8
ii. Radiological diagnosis of peri-implantitis	10
iii. Classification of peri-implantitis	10
5. TREATMENT CONCEPTS	10
i. Prevention and maintenance	10
iii. Surgical therapy	12
III. DISCUSSION :	13
IV. CONCLUSION	15
V. REFERENCES	16

INDEX OF FIGURES

Figure 1:25

Figure 2:25

Figure 3:26

Figure 4:26

Figure 5:27

Figure 6:27

Figure 7:28

TABLE INDEX

Table 1 : Classification of peri-implantitis.....	24
Table 2 : Comparison between teeth and implants	24

INDEX OF ABBREVIATION

BIC : Bone To Implant Contact

MBL : Marginal Bone loss

HA : Hydroxyapatite

BP : Biphosphonate

PTG : Porous Titanium Granules

PPD : Probing Pocket Depth

BOP : Bleeding On Probing

CAL : Clinical Attachment Level

I. INTRODUCTION

Today, inserting a dental implant represents a safe choice following a rigorous protocol, providing a comfortable and permanent tooth replacement as an alternative to removable dentures and conventional bridges. Favorable conditions for placing a dental implant were examined and defined in order to assure its sustainability and limit the indications of implant placement, in order to avoid failures. However, increasing evidence shows the possibility of development of peri-implant tissue inflammation, affecting the surrounding tissues. This inflammation can be either reversible affecting only the soft tissues: peri-implant mucositis, or irreversible attacking both soft and hard tissues, it is called peri-implantitis. Peri-implantitis is a site-specific infectious disease that causes an inflammatory process in soft tissues and bone loss around an osseointegrated implant in function. The etiology of the implant infection is conditioned by the status of the tissue surrounding the implant, implant design, degree of roughness, external morphology, and excessive mechanical load. The microorganisms most commonly associated with implant failure are spirochetes and mobile forms of gram-negative anaerobes, unless the origin is the result of simple mechanical overload. Diagnosis is based on changes of color in the gingiva, bleeding and probing depth of peri-implant pockets, suppuration, X-ray, and gradual loss of bone height around the tooth. (Lindhe. 2008)

1. Definitions

The term peri-implantitis was introduced more than two decades ago by Levison in 1965 and Mombelli in 1997, to describe pathological conditions of infectious nature around implants.

At the first European Workshop on Periodontology in 1993, two disease patterns associated with oral implants were identified and defined: Peri-implant mucositis and peri-implantitis. (Lindhe. 2008)

During the Sixth European Workshop on Periodontology in 2008, it was confirmed that peri-implant diseases are infectious and the lack of marked microbiological differences between mucositis and peri-implantitis may reflect the fact that, in most cases, the disease develops from mucositis to peri-implantitis. Peri-implant mucositis describes an inflammatory lesion that resides in the mucosa, may be identified clinically by redness and swelling of the soft tissue, but bleeding on probing is currently recognized as the important feature. It is a reversible process surrounding a functioning implant. While in peri-implantitis the mucosal lesion is often associated with suppuration and deepened pockets, but always accompanied by loss of supporting marginal bone. It is a progressive and irreversible disease. (Fig.1) (Lindquist. 1997)

II. RESULTS

1. ANATOMIC AND HISTOLOGICAL CONSIDERATIONS

i. Peri-Implant mucosa

The soft tissue that surrounds dental implants is termed peri-implant mucosa. The outer surface of the peri-implant mucosa is also covered by a keratinized oral epithelium, which in the marginal border connected with a thin barrier epithelium that faced the abutment part of the implant. The connective tissue in the compartment above the bone appeared to be in direct contact with the surface of the implant. The collagen fibers in this connective tissue apparently originated from the periosteum of the bone crest and extend towards the margin of the soft tissue in directions parallel to the surface of the abutment.(Lindhe. 2008)

ii. Attachment apparatus

Healing of the mucosa results in the establishment of a soft tissue attachment (transmucosal attachment) to the implant. This attachment serves as a seal that prevents products from the oral cavity reaching the bone tissue, and thus ensures osseointegration and the rigid fixation of the implant. The biologic width is established within 6-8 weeks around a trans mucosal implant. The apical seal of the implant sulcus is less resistant to periodontal probing (Mombelli et al. 1997; Sucleanet et al. 1997).

2. PHYSIOLOGIC CONSIDERATIONS

i. Osseointegration

Osseointegration has been described by Branemark (1983) , as consisting of a highly differentiated tissue making “a direct structural and functional connection between ordered, living bone and the surface of a load-carrying implant”. In 2008 Albrektsson suggested a new definition of a Osseointegration: “ A process whereby clinically asymptomatic rigid fixation of alloplastic materials is achieved and maintained in bone during functional loading”.

3. ETIOLOGY AND RISK FACTORS OF MARGINAL BONE LOSS

In recent consensus meetings, peri-implantitis has been described as peri-implant pathology with multifactorial etiology, including implant related factors, clinician factors, and patients' factors. It is accepted that all implants will display some extent of bone loss after integration and through time of function. (Lindhe. 2008)

i. Microbial Factor

In 2011, Mombelli & Decaillet concluded that peri-implantitis may be viewed as a mixed anaerobic infection and that in most cases the composition of the flora is similar to the subgingival flora at chronic periodontitis.

History of periodontitis

The presence of periodontal pathogens around failing implants could suggest a direct link between periodontitis and peri-implantitis, via a translocation of these species from their intra-oral niches to the freshly inserted implants (Heitz-Mayfield et al., 2010)

Poor oral hygiene

Plaque accumulation adjacent to dental implants is clearly associated with the development of peri-implant mucositis. Dental floss is usually recommended in conjunction with interproximal oral hygiene practices to achieve and maintain healthy oral conditions. (Maruyama, 2014)

Endodontic infection

The presence of untreated or insufficiently treated endodontic infections adjacent to the site of implant placement can adversely affect the outcome (Lindhe, 2008)

ii. Periodontal tissues

Tissue architecture

Tissue architecture is defined as the distance between the contact point between two neighboring teeth and a line connecting the mid-facial soft tissue margin of these teeth, has been categorized as flat or scalloped. Studies reported that high scalloped tissues have a higher risk to undergo recession. In contrast, flat tissue scallop tends to mimic the underlying osseous scallop facially. The greater the discrepancy is the scallop and higher is the risk for recession

(Lindhe, 2008)

Bone quality

Mineral density, microarchitecture, and trabecular thickness were indicated as defining factors for bone quality. Lekholm and Zarb determined in 1985 four types of bone depending of their proportion of cortical and cancellous bone on radiographic appearances. (Fig.2) (Renvert, 2008)

iii. Implant properties

Implant surface

It can occur that the coronal portion of the implant, which was initially designed to facilitate osseointegration, become exposed to the oral environment as a result of peri-implantitis. Some types of rough-surfaced implants, for instance those coated with hydroxyapatite (HA), were reported to have a higher incidence of complications. (Renvert. 2015)

Implant shape

In a study by De Bruyn (2010), it was suggested that the higher insertion and removal torque forces reported with tapered implant have the advantage of achieving primary stability more easily, but also increase the stress in the surrounding bone, which is highest in the cortical area around the implant neck and induces more bone loss. The ultimate goal of the scalloped implant design is to minimize the remodeling process seen around implants, thus improving the quality of survival by maintaining three dimensional osseous and soft tissue contours. (Salvi. 2004)

Microthreads

Recently, it was also claimed by several manufacturers that the introduction of retention grooves (microthreads) at the neck of the implant may further reduce the amount of bone loss following the implant installation.(Bratu. 2009)

Implant length and diameter

A systematic review of marginal bone loss showed that short dental implants (<10mm) had similar peri-implant marginal bone loss as standard implants (≥ 10 mm) for implant- supported fixed prostheses. It was suggested that ultra-short implants (6mm long) had an acceptable outcome as also did wide diameter short implants (5 and 6 mm) which had less marginal bone loss than implants 4.2 mm in diameter.(Van Velzen. 2016)

Bone level and tissue level

The initial depth of implant placement has very important clinical implications in terms of esthetics. In most 2-stage implant systems, after the abutment is connected, a microgap exists between the implant and abutment at or below the alveolar crest. In nonsubmerged implant designs, the implant itself extends above the alveolar crest level; therefore, such a microgap does not exist at the level of the bone.(Palacci et Ericsson. 2001)

iv. Surgery and implant placement

Surgical trauma has been regarded as one of the most commonly suspected etiologies proposed for early implant failure. (Palacci et Ericsson. 2001)

Flap design

The periosteal elevation has been speculated as one of the possible contributing factors for crestal implant bone loss. Vascular ischemia associated with flap reflection for second stage surgery has been implicated as a potential source of MBL (Marginal bone loss).(Berberi et al. 2014)

Wilderman et al. (1967) reported that the mean horizontal bone loss after osseous surgery with periosteal elevation is approximately 0.8mm, and the reparative potential is highly dependent upon the amount of cancellous bone existing underneath the cortical bone.

Implant position

In a study by Tarnow et al (2000) on the height of the inter-implant bone crest in relation to the inter-implant distance reported a lower height of the bone crest in areas with an inter-implant distance of <3mm as compared to areas with >3mm between the implants, and suggested that this difference may be the result of lateral bone loss at the implants.

Based on the finding from a 10-years longitudinal study that the amount of bone loss was of similar magnitude at implants with a neighbouring tooth and at those with a neighbouring implant, the authors concluded that presence of remaining teeth may not influence the marginal bone loss around an implant.(Fig.3) (Vandeweghe et al 2012).

The limitations on bone thickness at the anterior of the maxilla and the mandible and anatomic variations, such as concavity of the buccal aspects of the bone, can make it difficult to place a dental implant in the proper position to achieve the best esthetic results. In these cases, titled implants are used. The term titled implants refers to implants placed at an angle of normally 30 degrees or more with respect to axially or vertically positioned implants.(Parma-Benfenati. 2013)

Ata-Ali et al. (2013) conducted a literature review on titled implants from 1999 through 2010 and concluded that there was no evidence of differences in the success rates between tilted and axial implants. In another paper it was concluded that resorption in buccal areas may be less intensive as the angulation of placed implants increases towards the palatal area in the maxilla, where as for the mandibule a greater inclination towards the lingual area could be negative. In the mandibular,

when the implant is slightly angulated in the direction of the distal area, bone resorption seemed to be more marked in the buccal area.

Overheating and pressure

In 1984, Eriksson and Albrektsson reported that the critical temperature for implant site preparation was 47°C for 1 minute or 40°C for 7 minutes. When the bone is overheated the risk of implant failure is significantly increased. Matthews and Hirsch demonstrated that temperature elevation was influenced more by the force applied than drill speed. (Berberi et al. 2014)

v. Prosthetic aspects

Abutment considerations

Atieh et al. (2010) conducted a systematic review on the clinical relevance of platform switching and preservation of peri-implant crest bone levels.

Through the selection of a shorter abutment the mucosa can be compressed. Results indicate that the choice of a shorter abutment may increase MBL. (Galindo-Moreno et al. 2014)

Occlusal factor: stress and number of implants

Occlusal overload can result in progressive marginal bone loss or even complete loss of osseointegration, and when traumatic occlusion is combined with inflammation, the progression of bone destruction is accelerated. Contributing factors associated with increased bending overload in dental implants include: prostheses supported by 1 or 2 implants in the posterior region, straight alignment of implants, significant deviation of the implant axis from the line of action, high crown/implant ratio, and excessive cantilever length, discrepancy in dimensions between the occlusal table and implant head and parafunctional habits.(Palacci et al. 2001)

The survival of implant-supported fixed prostheses by a smaller number of implants shows good results both in the mandible and in the maxilla. In this context, it is suggested that the fewer implants in total rehabilitation, the better. (Persson et al. 2014)

Excess of cement

Wilson (2008) found a correlation of 81% between excess cement left in the soft tissue and the occurrence of sulcular bleeding and/or suppuration. A biofilm may form on the cement left in the peri-implant tissue. (Wohlfahrt et al. 2012)

Immediate Loading

During the one-stage surgery, the concept of immediate placement of definitive abutments and insertion of immediate interim prostheses appeared to protect the blood clot and to prevent interruption of the early mineralization of marginal bone. This was in contrast with several studies that reported no differences in MBL between immediate and delayed loading of dental implants. This phenomenon was more obvious in fresh extraction sockets, which demonstrated early MBL during the first 8 weeks, after which a constant marginal bone height was observed over 5 years. Two-phase surgical procedures have been associated with continuous MBL of between 0.01 and 0.02 mm/year, which could be in part related to the additional surgical procedure. During the removal of cover screws and tightening of implant abutments, greater stress is delivered to the initially mineralizing marginal bone; this manipulation could interface with the healing process and thus result in increased MBL. (Attieh et al. 2010)

vi. Systemic factors

General risk factors are factors related to the individual and factors that may influence the patient's susceptibility to infection.

Smoking

Tobacco consumption, in a dose-dependent manner, represents the third risk factor for the progression of periodontal disease. Tobacco negatively affects the outcome of almost all therapeutic procedures performed in the oral cavity. However, it was suggested that increased implant failure in smokers is not the result of poor healing or osseointegration, but because of exposure of peri-implant tissues to tobacco smoke. (Koldslund. 2010)

Smoking upregulates the expression of pro-inflammatory cytokine, which contributes to increased tissue damage and alveolar bone resorption. Lindquist reported significantly greater marginal bone loss around implants in heavy smokers (>14 cigarettes per day) than in those with low cigarette consumption (<14 cigarettes per day).(Mailoa. 2014).

Effects of smoking on implant survival and success are more pronounced in areas of poor quality trabecular bone. In smokers, maxillary implants have more failure rate as compared to mandibular implants. Probably because maxillary bone is of lower quality and consequently more susceptible to the damaging effects of smoking. (Kazat. 2012)

Diabetes mellitus

Although there is a slight tendency for more failures of implants in a diabetic compared to a non-diabetic population, the risk is not substantial in patients who are under good metabolic control. In the general population the 5-year overall success rate for implants is approximately 95%, where as in a diabetes population the rate is approximately 86%. Diabetes under suboptimal metabolic control often experience wound-healing difficulties and have an increases susceptibility to infections due to a variety of problems associated with immune dysfunctions. (Lindhe. 2008)

Alcohol consumption

Alcohol consumption may cause a vitamin K deficit disrupting the production of prothrombin, thus affecting coagulation mechanisms. Only one study concluded that peri-implant marginal bone loss was statistically linked to alcohol consumption > 10g per day and that alcohol induced more serious peri-implantitis than cigarettes. (Oltra. 2013)

Post-menopausal osteoporosis

A study by Dvorak et al. (2011) found no relation between osteoporosis and peri-implantitis in adult women despite the high success rates of implants placed in patients taking BP(bisphosphonate) complications have been reported.

Data from a study by Cohen et al. (2011) suggested that patients taking BP may be at greater risk of peri-implant bone loss (BP inhibit osteoclast action and thereby bone resorption)

Hyposalivation

Hyposalivation could be a risk factor for peri-implantitis. In fact, decrease of salivary flow was often accompanied by a change in its composition and reducing bacterial clearance in the oral cavity. (Lindhe. 2008)

4. DIAGNOSIS

i. Clinical diagnosis

Peri-implant lesions are commonly asymptomatic and frequently detected in follow up visits. These lesions are clinically defined by the presence of redness and swelling of the mucosa, bleeding and/or suppuration on probing, deepening of the pockets adjacent to the dental implants,

and loss of the implant-supporting bone. Palpation reveals pus, swelling and pain, and the exudation of grafting practices. (Lindhe. 2008)

Probing

Probing is essential for diagnosis of peri-implant diseases. In the European consensus report, it was concluded that the probing depth, the presence of BOP (Bleeding On Probing) and suppuration should be assessed regularly for the diagnosis for peri-implant diseases.(Colet.2011)

Probing Pocket Depth (PPD) is the distance from the edge of peri-implant tissue to the bottom of peri-implant sulcus/pocket and clinical attachment level (CAL) is the distance from the implant platform or connection area to the bottom of peri-implant sulcus/pocket. (Ferreira. 2014)

An increase in probing depth over time is associated with the loss of attachment and supporting bone. Because healthy implants generally have probing depths that are less than 4mm, peri-implant pockets of 5 mm or more should be regarded as an indicator of bone loss and hence, a radiographic evaluation is required. Also, peri-implant hyperplasia is often found in an area of absence of keratinized gingiva or the overflow of supra-implant structures. (Oltra. 2013)

Heitz-Mayfield (2008) concluded that probing using a light force (0.25N) does not damage the peri-implant tissues. BOP represents histological inflammatory tissue changes.

Suppuration

The presence of pus is always a sign of infection associated with destruction of peri-implant tissues. When finger pressure is exerted on the peri-implant mucosa, it is common to observe pus discharge. This phenomenon is never present in the case of a peri-implant mucositis.(Heitz-Mayfield. 2010)

Implant mobility

Presence or absence of mobility is checked digitally or with the help of instruments trying to move the implants. A perceived mobility of the restoration per se does not necessarily mean that the implant is loose. The connection suprastructure/abutment and/or abutment/implant might be loose leading to the mobility. (Lindhe. 2008)

Implant mobility is not used to diagnose peri-implantitis because it indicates the complete loss of osseointegration and the failure of the implant. Osstell uses Resonance Frequency Analysis to determine implant stability and osseointegration.(Ferreira. 2014)

ii. Radiological diagnosis of peri-implantitis

Radiographic examination allows clinicians to assess the relationship between implants and prosthetic components. In addition, they are required to evaluate supporting bone levels around implants. Hence, regular radiographical check-up for marginal bone loss has been emphasized for early detection of peri-implantitis. Periapical radiography using fixed angulators to prevent image deformation is often used to verify marginal bone level or interproximal bone loss in peri-implantitis. (Ferreira. 2014)

The use of digital image analysis had expanded into implant dentistry to monitor peri-implant bone healing and gain or loss of alveolar bone density, as well as infrabony lesions in three planes, true to scale and without any overlay or distortion. (Oltra. 2013)

Peri-implantitis lesions appear crater like or saucer-shaped defects. It is essential to differentiate a biological process (saucerization) from a pathological one (peri-implantitis). Saucerization is a biological process of peri-implant cervical bone remodeling starting in the first year after implant placement that is observed radiographically around certain implant type. It ranges from 0.4mm to 1.6mm within the first year and then approximately 0.1 mm/year. (Palacci. 2001)

iii. Classification of peri-implantitis

To date, there have been no standardized parameters to clinically differentiate the various stages and severities of peri-implantitis. A proposed classification by Rosen et al. (2012) is based on three distinct clinical stages of peri-implantitis: early, moderate, and advanced. It is depending on Pocket depth and bone loss. (Table. 1)

5. TREATMENT CONCEPTS

Although peri-implantitis is reported to be a common problem, there is lack of scientific guidelines in how to treat peri-implantitis. The ideal goal of the treatment of peri-implantitis would be the resolution of disease, i.e. no suppuration or bleeding on probing, no further bone loss, and the reestablishment and maintenance of healthy peri-implant tissues, knowing that reosseointegration on a previously contaminated implant surface is possible. (Sahm. 2011)

i. Prevention and maintenance

The prognosis of the implant is highly dependent on appropriate case selection, recall sessions for maintenance and primary and secondary prevention. (Simons. 2015)

ii. Non-surgical therapy

It was stated that non-surgical treatment is recommended for marginal bone loss less than 2mm around implant and surgical treatment is recommended for marginal bone loss greater than 2mm.(Simons. 2015)

Mechanical debridement

Different types of curettes have been studied and most of the protocols included an adjunctive polish with a rubber cup and polishing paste (fluor of pumice, nupro Fine, tin oxide). Steel curettes have an external hardness higher than titanium and accordingly are not indicated for cleaning titanium implants. Titanium-coated curettes have a similar hardness to the titanium surface and thus do not scratch its surface. Carbon-fiber curettes are softer than the implant surface and therefore remove bacterial deposits without damaging the surface, although they break easily. (Fig.4) Teflon curettes have similar properties to carbon-fiber curettes. Plastic curettes are the most fragile of all curette types and have limited debriding capacity.(Figuro. 2014)

Ultrasonic devices

Ultrasonic devices with polyetheretherketone coated tips have been used to debride the implant surface easily and is comfortable for the patient.(Figuro. 2014)

The study by Karring and al. (2005) demonstrated that sub-mucosal debridement alone, accomplished by utilizing either an ultrasonic device or carbon fiber curettes, is not sufficient for the decontamination of the surface of implants with peri-implant pockets bigger than 5mm and exposed implant threads.

Air abrasion

Recently, a powered air abrasive system, based on a low-abrasive amino-acid glycine powder, has been demonstrated as an effective method of biofilm removal from the implant surface. (Figuro. 2014)

Adjunctive use of antimicrobial products :

Adjunctive therapies, such as antiseptics and antibiotics, have been proposed to improve the results of nonsurgical debridement. (Lang. 2011)

The addition of antiseptic therapy (Chlorhexidine-based products) to mechanical debridement, seems to provide additional clinical improvements in deep peri-implant lesion mean PPD > 5mm. (Renvert et al. 2006)

The study by Renvert et al. (2008) demonstrated that the adjunctive benefits derived from the addition of an antibiotic to mechanical debridement tend to be greater, although to a limited extent, than those achieved by the combined use of an antiseptic (chlorhexidine) and mechanical debridement.

Significant reductions in bleeding on probing were found after combining mechanical therapy with the use of a tetracycline-containing fiber. There are no clinical trials available nowadays on the systemic administration of antibiotics for the therapy of peri-implantitis. (Sahm. 2011)

iii. Surgical therapy

In the many patients with advanced lesions, mechanical nonsurgical therapy alone is insufficient in the treatment of peri-implantitis and a surgical intervention is often needed. The primary aim of such a procedure is to provide access for decontamination of the infected implant surface in order to allow undisturbed healing and reduce the risk for further disease progression. The decision on whether to use a resective or a regenerative surgical technique depends on the clinical situation. However, even if surgery seems to be the therapy of choice, nonsurgical therapy should always be performed before surgical interventions. (Figuro. 2014)

Access flap surgery and implant surface decontamination.

The objective of the access flap surgery intervention is to conserve and to maintain all the soft tissues around the affected implant and to focus mainly on the decontamination of the implant surface. Usually, intracrevicular incisions are made around the affected implants and mucoperiosteal flaps are raised both buccally and palatally/lingually. As this technique aims to maintain the position of the soft-tissue margin around the implant neck, this can only be attained when the peri-implant bone loss is shallow. Apically positioned flaps have been advocated in order to enhance self-performed oral hygiene and reduce the pockets around the affected implants. Numerous approaches have been used for implant surface decontamination during peri-implant surgery, including mechanical, chemical, laser treatments, photodynamic therapy. The rationale for the use of chemical treatments is to disinfect/decontaminate the implant surface by direct application of appropriate substances. Citric acid, hydrogen peroxide, chlorhexidine and/or saline have been utilized, and all have given similar results in experimental studies. (Figuro. 2014)

Photodynamic therapy generates reactive oxygen species by multiplicity with help of a high-energy single-frequency light (e.g. diode lasers) in combination with photosensitizers (e.g. toluidine blue). As a recommendation, photodynamic therapy has to be considered as an additional treatment option.(Thomas. 2009) (Fig.5)

Regenerative therapy

In this technique, intracrevicular incisions are often performed in order to maintain the total amount of soft tissues. Degranulation of the defect is performed using titanium instruments. And a graft is placed around the implant, filling the intrabony component of the defect. Grafting may be performed with either autologous bone or bone substitutes. The graft may be covered with a resorbable or a nonresorbable membrane (Fig.6). Finally, the flaps are coronally positioned and sutured in order to determine healing. Following mechanical decontamination, the implant surface and the wound area should be rinsed with sterile saline solution for a minimum of 2min.

Reconstruction with PTG (Porous Titanium Granules) resulted in significantly better radiographic peri-implant defect fill.(Figuero. 2014)

III. DISCUSSION :

Treatment of peri-implant mucositis and peri-implantitis must be focused on early diagnosis and controlling the risk factors or indicators to prevent it from occurring.

In a non-surgical approach to treat peri-implantitis, local debridement was used to clean the surface of implants. Instruments softer than titanium, such as polishing with a rubber cup and paste, floss, interdental brushes, or using plastic scaling instruments have been shown not to roughen the implant surface unlike metal and ultrasonic scalers. (Matarasso. 1996). Although implant surface damage can almost be prevented by using either ultrasonic scalers with a nonmetallic tip or resin/carbon fiber curettes, the presence of implant threads and/or implant surface roughness may compromise the access for cleaning. (Schou. 2004)Another study demonstrated that sub-mucosal debridement alone, accomplished by utilizing either an ultrasonic device or carbon fiber curettes, is not sufficient for the decontamination of the surfaces of implants with peri-implant pockets ≥ 5 mm and exposed implant threads. (Karring.2005). So it seems reasonable to suggest that mechanical or ultrasonic debridement alone may not be an adequate modality for the resolution of peri-implantitis.

Treatment of peri-implant infection by mechanical debridement with plastic curettes combined with antiseptic (0.2% chlorhexidine) therapy may lead to significant improvements in bleeding on

probing, peri-implant probing pocket depth, and clinical attachment level in 6 months interval.(Schwarz.2008) This contradicts with another study where the addition of antiseptic therapy to mechanical debridement does not provide adjunctive benefits in shallow peri-implant lesions where the mean probing pocket depth was <4 mm. (Renvert.2008)

Patients suffering from localized peri-implant problems in the absence of other infections may be candidates for treatment by local drug-delivery devices. Local application of antibiotics by the insertion of tetracycline fibers for 10 days can provide a sustained high dose of the antimicrobial agent precisely into the affected site for several days. (Lang.2000)

The use of minocycline microspheres as an adjunct to mechanical therapy is beneficial in the treatment of peri-implant lesions, but the treatment may have to be repeated. A study showed that the adjunctive benefits derived from the addition of an antibiotic minocycline to mechanical debridement tend to be greater, although to a limited extent, than those achieved by the combined use of an antiseptic (chlorhexidine) and mechanical debridement.(Renvert.2008)

If the problem is generalized, specific microbiological information is collected and antibiotics are administered systemically. If peri-implantitis is associated with persisting periodontal disease, then both conditions need to be treated. In this case, the adjunctive use of systemic antibiotics may be considered. There are no clinical trials available nowadays on the systemic administration of antibiotics for the therapy of peri-implantitis. (Lang.2000)

Provided that mechanical and antiseptic protocols are followed prior to administering antibiotic therapy, it appears that shallow peri-implant infection may be successfully controlled using antibiotics. But it is still controversial whether deeper peri-implant lesions can be adequately treated non-surgically by a combination of a local antibiotic and mechanical debridement. Thus surgical techniques to treat peri-implantitis might be necessary.

Surgical resection is generally confined to implants placed in non-aesthetic sites. Surgical flap helps in comprehensive debridement and decontamination of the affected implant. Surgical therapy can be by placing autogenous bone grafts covered by membranes, autogenous bone grafts alone, membranes alone, or a control access flap procedure. It was shown that defects treated with membrane-covered autogenous bone demonstrated significantly larger amounts of bone regeneration and reosseointegration than those treated with the other three procedures. However, membrane exposure is a frequent complication after such procedures. (Schou.2004) As conclusion, the combination of guided bone regeneration with either demineralized freeze-dried

bone or resorbable hydroxyapatite appears to be the treatment of choice for plaque-induced peri-implant defects. (Hürzeler.1997)

A randomized comparative clinical trial concluded that resective surgical procedures coupled with implantoplasty could have a positive influence on the survival rates of rough-surfaced implants affected by peri-implantitis as well as on peri-implant clinical parameters, such as pocket-probing depth, suppuration, and sulcus bleeding. (Romeo.2005,2007)

In another study, nanocrystalline hydroxyapatite and guided bone regeneration provided clinically significant improvements in clinical parameters. Following up 2-year results, both treatment modalities were efficient in providing clinically significant reductions of pocket-probing depth and gains in clinical attachment level. The combination of application of natural bone mineral and collagen membrane seemed to correlate with greater improvements in those clinical parameters and, hence, was associated with a more predictable and enhanced healing outcome. (Schwarz.2000,2006)

In a recent 2-11-year retrospective study study, long-term outcome of surgical treatment of peri-implantitis was investigated. The treatment included oral hygiene instruction, professional supra-mucosal instrumentation, and surgical therapy aiming at pocket elimination. The results of the study revealed that surgical treatment of peri-implantitis was effective in the long-term, the outcome was better at implants with non-modified than with modified surfaces, and preservation of crestal bone support was consistent with healthy peri-implant tissue conditions. (Berglundh.2018)

IV. CONCLUSION

Peri-implant diseases are important disease entities as a result of their high prevalence and the lack of a standard mode of therapy. Patient selection is a key factor in the implant therapy; a thorough study of the patient's local and systemic risk factors is important before any implant treatment. Risk factors are also practitioner dependent (surgical trauma, implant choice and positioning...) Surgical techniques may be necessary to provide us with adequate access to degranulate the inflamed tissues effectively as well as to decontaminate and, if indicated, modify the implant surface. Before surgical techniques are employed, nonsurgical therapy and reinforcement of the oral hygiene should be performed. Regular follow-up appointments and close monitoring of the treated sites is, of course, important for preventing relapse.

V. REFERENCES

- Albrektsson, T. (2008). Hard tissue implant interface. *Australian Dental Journal*, 53(Suppl), pp. S34-S38.
- Atieh, M., Ibrahim, H., Atieh, A. (2010). Platform Switching for Marginal Bone Preservation Around Dental Implants: A Systematic Review and Meta- Analysis. *Journal of Periodontology*, 81(10), pp. 1350-366.
- Berberi, A., *et al.* (2014). Influence of Surgical and Prosthetic Techniques on Marginal Bone Loss around titanium Implants. Part I: Immediate Loading in fresh Extraction Sockets. *Journal of Prosthodontics*, 23(7), pp. 521-527.
- Berglundh, T., Wennström, J.L., Lindhe, J. (2018). Long-term outcome of surgical treatment of peri-implantitis. A 2-11-year retrospective study. *Clinical oral implants Research*, Disponivel em: <<https://doi.org/10.1111/clr.13138>>.
- Brånemark, P.I. (1983). Osseointegration and its experimental background. *Journal of Prosthetic Dentistry*. 50(3), pp. 399-410.
- Bratu, E.A., Tandlich, M., Shapira, L. (2011). A rough surface implant neck with microthreads reduces the amount of marginal bone loss: a prospective clinical study. *Clinical Oral Implants Research*. 20(8), pp. 827-32.
- Colet, D., *et al.* (2011). Peri-implantitis: Literature Review. *Dental Press Periodontal Implant Dentistry*. 5(4), pp. 56-65.
- Dvorak, G., *et al.* (2011). Peri-implantitis and late implant failures in postmenopausal women: a cross-sectional study. *Journal of Clinical Periodontology*. 38(10), pp. 950-5.
- Eriksson, A., Albrektsson, T., Albrektsson, B. (1984). Heat caused by drilling cortical bone Temperature measured in vivo in patients and animals. *Acta Orthopaedia Scandinavica*. 55(6), pp. 629-631.
- Ferreira, R., *et al.* (2014). Peri-implantitis: Critical an current overview of etiological factors, clinical/radiografic diagnosis and prognosis. A literature review. *Dental Press Implantology*. 8(3), pp. 76-84.

Figüero, E., et al. (2014). Management of peri-implant mucositis and peri-implantitis. *Periodontology 2000*, 66, pp. 255-273.

Galindo-Moreno, P., et al. (2014). Prosthetic Abutment Height is a key Factor in peri-implant Marginal Bone Loss. *JDR Clinical. Suppl*, pp. 80S-85S.

Heitz-Mayfield, L., Lang, N. (2010). Comparative biology of chronic and aggressive periodontitis vs. peri-implantitis. *Periodontology 2000*. 53, pp. 167-181.

Heitz-Mayfield L. (2008). Peri-implant diseases: diagnosis and risk indicators. *Journal of Clinical Periodontology*. 8(Suppl), pp. 292-304.

Hürzeler, M.B., et al. (1997). Treatment of peri-implantitis using guided bone regeneration and bone grafts, alone or in combination, in beagle dogs. Part 2: Histologic findings. *International Journal of Oral & Maxillofacial Implants*. 12(2), pp. 168-75.

Karring E.S., et al. (2005). Treatment of periimplantitis by the Vectors system. A pilot study. *Clinical Oral Implants Research*. 16, pp. 288–93.

Kasat, V., Ladda, R. (2012). Smoking and dental implants. *Journal of International Society of Preventive and Community Dentistry*. 2(2), pp. 38-41.

Koldslund, O.C., Scheie, A.A., Aass, A.M. (2010). Prevalence of peri-implantitis related to severity of the disease with different degrees of bone loss. *Journal of Periodontology*. 81(2), pp. 231-8.

Kotsovilis, S., et al. (2008). Therapy of peri-implantitis: a systematic review. *Journal of Clinical Periodontology*. 35, pp. 621-629.

Lang, N.P., Berglundh, T. (2011). On behalf of working Group 4 of the seventh European Workshop on Periodontology: Peri-implant diseases: where are we now? – Consensus of the seventh European Workshop on Periodontology. *Journal of Clinical Periodontology*. 38(11 Suppl), pp. 178-181.

Lang, N.P., Wilson, T.G., Corbet, E.F. (2000). Biological complications with dental implants: Their prevention, diagnosis and treatment. *Clinical Oral Implants Research*. 11(Suppl 1), pp. 146–55.

Lindhe, J., Lang, N., Karring T. (2008). Clinical Periodontology and implant dentistry. *Wiley-Blackwell*, 5(1).

Lindhe, J., Meyle, J. (2008). Peri-implant diseases: consensus Report of the Sixth European Workshop on Periodontology. *Journal of Clinical Periodontology*. 35(Suppl.8), pp. 282-285.

Linquist, L.W., Carlsson, G.E., Jemt, T. (1997). Association between marginal bone loss around osseointegration mandibular implants and smoking habits: a 10-year follow-up study. *Journal of Dental Research*. 76(10), pp. 1667-74.

Maruyama, N., *et al.* (2014). Intraindividual variation in core microbiota in peri-implantitis and periodontitis. *Scientific Reports*. 4, p. 6602.

Matarasso, S., *et al.* (1996). Maintenance of implants: An in vitro study of titanium implant surface modifications subsequent to the application of different prophylaxis procedures. *Clinical Oral Implants Research*. 7, pp. 64–72.

Mombelli, A., *et al.* (1997). Comparison of periodontal and peri-implant probing by depth-force pattern analysis. *Clinical Oral Implants Research*. 8, pp. 448-454.

Mombelli, A., De'caillet, F. (2011). The characteristics of biofilms in peri-implant disease. *Journal of Clinical Periodontology*. 38(Suppl.11), pp. 203-213.

Oltra, D., *et al.* (2013). Rehabilitation of the Atrophic Maxilla with Tilted implant: review of the literature . *Journal of Implantology*. 39(5), pp. 625-32.

Palacci, P., Ericsson, I., (2001). Esthetic Implant Dentistry; Soft And Hard Tissue Management. *Quintessence Books, Chicago*.

Parma-Benfenati, S., Roncati, M., Tinti, C. (2013). Treatment of Peri-Implantitis: Surgical Therapeutic Approaches Based on Peri-implantitis Defects. *International Journal of Periodontics Restorative Dentistry*. 33, pp. 627-633.

Persson, G., Renvert, S. (2014). Cluster of bacteria Associated with Peri-implantitis. *Clinical Implant Dentistry and Related Research*. 16(6), pp. 783-93.

Renvert, S., Quirynen, M. (2015). Risk indicators for peri-implantitis. A narrative review. *Clinical Oral Implants Research*. Suppl. 11, pp. 15-44.

Renvert, S., Roos-Jansaker, A.M., Claffey, N. (2008). Non-surgical treatment of peri-implant mucositis and peri-implantitis: a literature review. *Journal of Clinical Periodontology*. 35(Suppl.8), pp. 305-315.

Renvert, S., *et al.* (2008). Mechanical and repeated antimicrobial therapy using a local drug delivery system in the treatment of peri-implantitis: A randomized clinical trial. *Journal of Periodontology*. 79, pp. 836–44.

Romeo, E., *et al.* (2005). Therapy of peri-implantitis with resective surgery. A 3-year clinical trial on rough screw-shaped oral implants. Part I: Clinical outcome. *Clinical Oral Implants Research*. 16, pp. 9–18.

Romeo, E., *et al.* (2007). Therapy of peri-implantitis with resective surgery. A 3-year clinical trial on rough screw-shaped oral implants. Part II: Radiographic outcome. *Clinical Oral Implants Research*. 18, pp. 179–87.

Sahm, N., *et al.* (2011). Non-surgical treatment of peri-implantitis using an air-abrasive device or mechanical debridement and local application of chlorhexidine: a prospective, randomized, controlled clinical study. *Journal of Clinical Periodontology*. 38, pp. 872-878.

Salvi, G., Lang, N., (2004). Diagnostic Parameters for Monitoring Peri-implant Conditions. *International Journal of Oral Maxillofacial Implants*. 19(Suppl.), pp.116-127.

Schwarz, F., *et al.* (2008). Two year clinical results following treatment of peri-implantitis lesions using a nanocrystalline hydroxyapatite or a natural bone mineral in combination with a collagen membrane. *Journal of Clinical Periodontology*. 35, pp. 80–7.

Schwarz, F., *et al.* (2006). Healing of intrabony peri-implantitis defects following application of a nanocrystalline hydroxyapatite (Ostim) or a bovine-derived xenograft (Bio-Osst) in combination with a collagen membrane (Bio-Gidet). A case series. *Journal of Clinical Periodontology*. 33, pp. 491–9.

Peri-Implantitis: Etiology, Risk Factors and Treatment Concepts

Schwarz, F., et al. (2008). Two year clinical results following treatment of peri-implantitis lesions using a nanocrystalline hydroxyapatite or a natural bone mineral in combination with a collagen membrane. *Journal of Clinical Periodontology*. 35, pp. 80–7.

Tarnow, D., Cho, S., (2000). The effect of inter-implant distance on the height of inter-implant bone crest. *Journal of Periodontology*. 71(4), pp. 546-549.

Sculean, A., Gruber, R., Bosshardt, D. (2014). Soft tissue wound healing around teeth and dental implants. *Journal of Clinical Periodontology*. 41(Suppl.15), pp. S6-S22.

Schou, S., Berglundh, T., Lang, N.P. (2004). Surgical treatment of peri-implantitis. *International Journal of Oral Maxillofacial Implants*. 19(Suppl), pp. 140–9.

Simons, W., et al. (2015). The proportion of cancellous bone as predictive factor for early marginal bone loss around implant in the posterior part of the mandible. *Clinical Oral Implants Research*. 26, pp. 1051- 1059.

Thomas, G., Wilson, Jr. (2009). The positive Relationship Between Excess Cement and Peri-implant Disease: A Prospective Clinical Endoscopic Study. *Journal of Periodontology*. 80(9), pp. 1388-1392.

Van Velzen, F., et al. (2016). Dental floss as a possible risk for the development of peri-implant disease: an observational study of 10 cases. *Clinical Oral Implants Research*. 27, pp. 618-621.

Vandeweghe, S., et al. (2012). The influence of implant design on bone Remodeling around Surface-Modified Southern Implant. *Clinical Implant Dentistry and Related Research*. 14(5), pp. 655-62.

Wohlfahrt, J., et al. (2012). Porous Titanium Granules in the surgical treatment of peri-implant osseous defects; a randomized clinical trial. *International Journal of Oral Maxillofacial Implant*. 27(2), pp. 401-10.

Table 1 Classification of peri-implantitis	
Early	PD ≥ 4 mm (bleeding and/or suppuration on probing*) Bone loss < 25% of the implant length†
Moderate	PD ≥ 6 mm (bleeding and/or suppuration on probing*) Bone loss 25% to 50% of the implant length†
Advanced	PD ≥ 8 mm (bleeding and/or suppuration on probing*) Bone loss > 50% of the implant length†

Table.1: Classification of peri-implantitis. (Rosen et al. 2012)

	Tooth	Implant
Connection	Cementum, bone, periodontal ligament	Osseointegration, ⁶³ functional ankylosis ⁶⁴
Junctional epithelium ⁶⁰⁻⁶²	Hemidesmosomes and basal lamina (lamina lucida, lamina densa zones)	Hemidesmosomes and basal lamina (lamina lucida, lamina densa, and a sublamina lucida zones)
Connective tissue ⁶⁰⁻⁶²	Perpendicular fibers	Parallel fibers
Vascularity ⁴³	More	Less
Probing depth	≤3 mm in health ⁶⁵	2.5 mm to 4.0 mm (dependent on soft tissue depth) ¹⁻²
Bleeding on probing	More reliable ⁶⁶	Less reliable ⁶⁷

Table.2: Comparison between tooth and implant. (Palacci et Ericsson. 2001)

Peri-Implantitis: Etiology, Risk Factors and Treatment Concepts

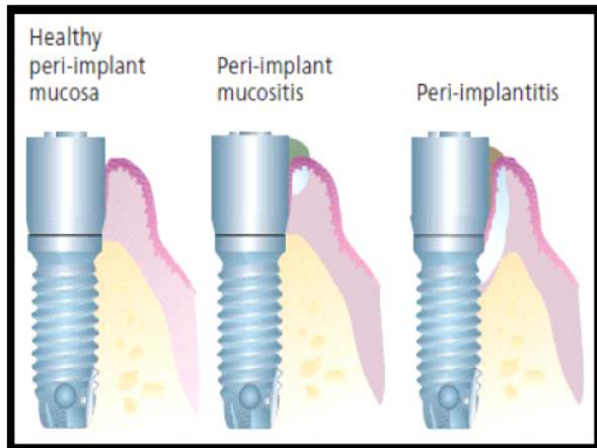


Fig.1: Peri-implant mucositis and peri-implantitis. (Linquist. 1997)

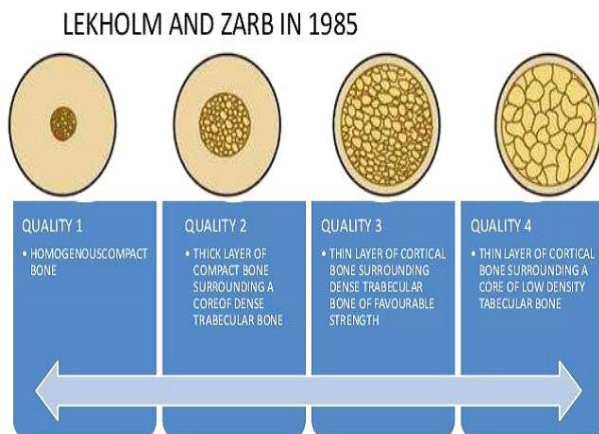

Fig.2 : Four types of bone (Renvers. 2008)

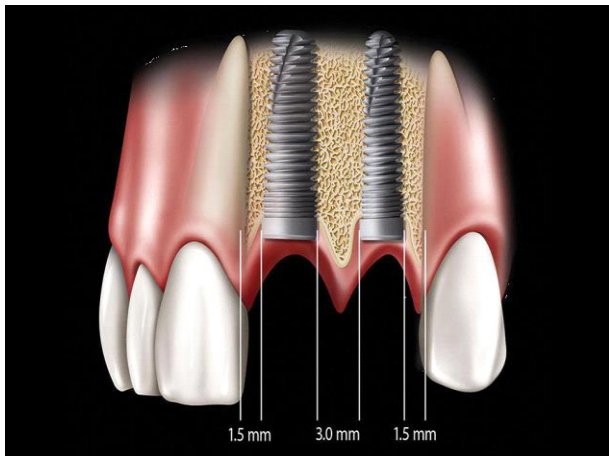


Fig.3: Ideal implant position. (Vandeweghe et al. 2012)

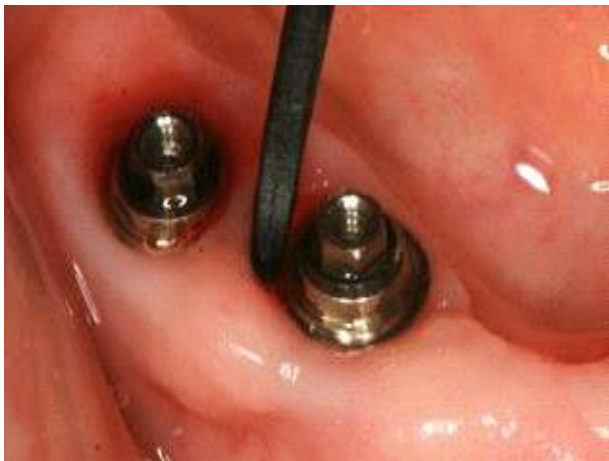

Fig.4: Carbon-fiber curette. (Figuero. 2014)

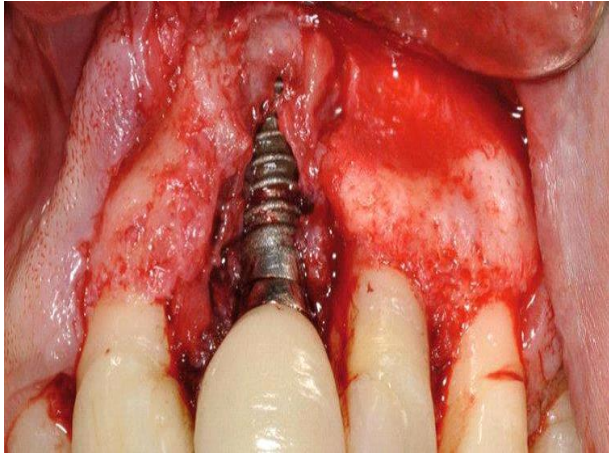


Fig.5: Access flap surgery: mucoperiosteal flap.(Figuero. 2014)

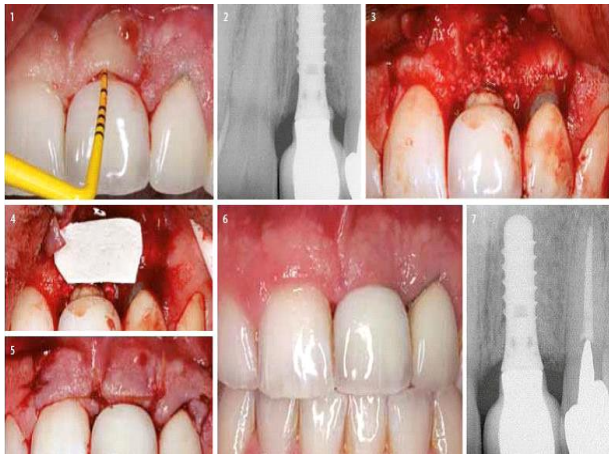

Fig.6: Regenerative surgery: Defect fill with substitute and resorbable membrane to cover the bone defect. (Figuero. 2014)

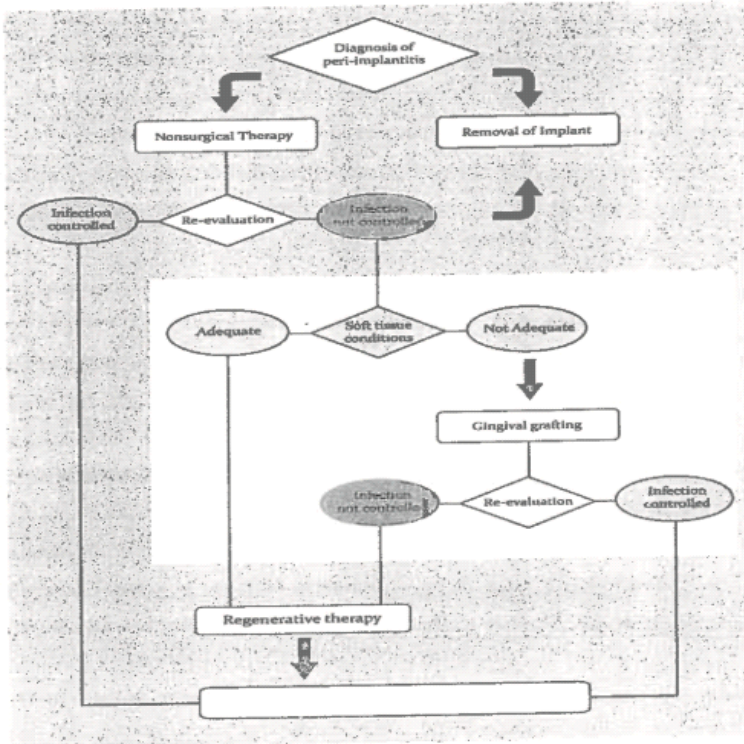


Fig.7: Sequence of treatment (Renvert. 2015)