

Francisco Fernández Sobrino

Histological differences of gingival autografts of various donor sites and clinical results in mucogingival surgery

Universidade Fernando Pessoa

Faculdade de Ciências da Saúde

Porto, 2020

Francisco Fernández Sobrino

Histological differences of gingival autografts of various donor sites and clinical results in mucogingival surgery

Universidade Fernando Pessoa

Faculdade de Ciências da Saúde

Porto, 2020

Francisco Fernández Sobrino

Histological differences of gingival autografts of various donor sites and clinical results in mucogingival surgery

Dissertação apresentada a Universidade Fernando Pessoa
Como parte dos requisitos para a obtenção do grau de
Mestre em Medicina Dentária

Atestando a originalidade do trabalho,

Abstract

Soft tissue grafting has become a substantial element in periodontal and implant mucogingival surgeries. The choice of donor site selection and the harvesting technique are two important factors to take into consideration.

The goal of this narrative review is to compare the histological characteristics and clinical results of gingival grafts harvested from the palatal and tuberosity areas, applied in mucogingival surgery procedures. The focus of analysis was on how their composition at a histological level correlate with the following clinical parameters: postoperative shrinkage, volume gain, stability, width of keratinized tissue gain, aesthetics and morbidity.

It was concluded that the location of the donor site and the grafting technique can affect the graft composition, which may have an impact in the clinical results of mucogingival procedures. More well design randomized clinical trials in mucogingival procedures comparing different types of grafts are needed to further elucidate potential differences in clinical outcomes.

Key words: autogenous gingival grafts, donor sites, tuberosity graft, palatal gingival grafts, mucogingival surgery

Resumo

Os enxertos autógenos gengivais tornaram-se um elemento substancial nas cirurgias periodontais e implantológicas mucogengivais. A escolha da seleção da área dadora e a técnica de colheita são dois fatores importantes a ter em conta.

O objetivo desta revisão narrativa é comparar as características histológicas e os resultados clínicos dos enxertos gengivais colhidos das áreas do palato e tuberosidade, aplicados nos procedimentos de cirurgia mucogengival. O foco da análise foi a forma como a sua composição a nível histológico se correlaciona com os seguintes parâmetros clínicos: contração pós-operatória, aumento de volume, estabilidade, aumento da largura de tecido queratinizado, estética e morbidade.

Concluiu-se que a localização da área dadora e a técnica de colheita podem afetar a composição do enxerto, o que pode ter um impacto nos resultados clínicos dos procedimentos mucogengivais. São necessários mais ensaios controlados randomizados em procedimentos mucogengivais para elucidar ainda mais as diferenças potenciais nos resultados clínicos.

Palavras chave: enxertos autógenos gengivais, sítios doadores, enxerto de tuberosidade, enxerto gengival de palato, cirurgia mucogengival

Acknowledgements

I would like to thank first of all my family and friends that have always supported me in this endeavor of coming to study abroad.

I was very lucky to have such good teachers in the field of Periodontics in the University of Buenos Aires such as Dr. Nelson Carranza and Dr. Carina Pacenza who introduce me to the surgical world in Periodontology and always push me to be better.

I want to extend my thanks to the University Fernando Pessoa for making this possible, and most importantly to Dr. Cristina Lima who has guided me and help me through this process.

Finally, I would also like to thank Dr. Sylvie Pereira for sharing her documentation of grafts with me.

Index

	Page
Introduction.....	1
Development.....	3
1. <i>Anatomical considerations</i>	3
2. <i>Harvesting safety zone</i>	4
3. <i>Thickness of palatal mucosa</i>	5
4. <i>Histological studies on gingival grafts</i>	7
i. <i>Proportion Of Lamina Propria And Submucosa</i>	7
ii. <i>Lamina Propria Thickness</i>	8
iii. <i>Tuberosity Grafts</i>	8
5. <i>Histological and Clinical studies comparing palatal versus tuberosity grafts</i>	9
Discussion.....	11
Conclusion.....	15
Bibliographical references.....	16

Index of acronyms and abbreviations

CT: connective tissue

CAF: coronally advanced flap

CEJ: cementoenamel junction

CTG: connective tissue graft

DGG: deepithelized connective tissue graft

TG: tuberosity graft

FGG: free gingival graft

STCG: subepithelial connective tissue graft

MMP: matrix metalloproteinases

LH: Lysyl hydroxylases

COL: collagen gene

Francisco Fernández Sobrino

**Histological differences of gingival autografts of various donor sites and clinical results
in mucogingival surgery**

Universidade Fernando Pessoa

Faculdade de Ciências da Saúde

Porto, 2020

Histological differences of gingival autografts of various donor sites and clinical results in mucogingival surgery

Introduction

A soft tissue graft is a withdrawal of soft tissue that is completely detached from its original donor site and placed in a prepared recipient bed (American Academy of Periodontology 2001).

Soft tissue grafting has become a substantial element in plastic periodontal surgery as well as implant surgical procedures. Clinical indications are mainly the treatment of recessions, peri-implant soft tissue deficiencies and soft tissue ridge augmentations. These procedures main objectives are augmenting tissue thickness, re-establishing an adequate width of keratinized tissue and improving aesthetics at teeth and dental implant sites (Sanz M. et alii. 2014, Zucchelli G. et alii. 2020). Specifically, in root coverage procedures indications are esthetics, to reduce tooth hypersensitivity and/or to create or augment keratinized tissue (Zucchelli G. et alii. 2015).

The critical elements on the use of soft tissue grafts are the donor site selection and the harvesting technique (Zuhr O. et alii. 2014).

In fact, different donor sites can be selected to harvest the autogenous grafts. Mainly two different locations can be used as regards the donor site: the anterior and the posterior palate, whereas the posterior area can be divided into the lateral palate and the tuberosity.

Additionally, there have been described different harvesting techniques used also according to the donor area. The most frequently reported at the anterior palate is the single incision technique (Hurzeler M. 1999, Lorenzana ER, Allen EP. 2000) and at the posterior palate the trap door technique (Bruno JF. 1994, Edel, A. 1974, Harris RJ. 1992, Langer B, Langer L. 1985). Nevertheless, in the lateral posterior area of the palate the other alternative is to harvest a free gingival graft (FGG) and de-epithelialized extraorally, obtaining a de-epithelialized gingival graft (DGG) (Zucchelli, G. et alii. 2010). Finally, at the tuberosity area the harvesting technique is done by performing a distal wedge (Jung UW. et alii. 2008) obtaining a tuberosity graft (TG) that also has to be deepithelialized extraorally. This results in 4 types of gingival autografts:

Histological differences of gingival autografts of various donor sites and clinical results in mucogingival surgery

1. STCG from the anterior palate

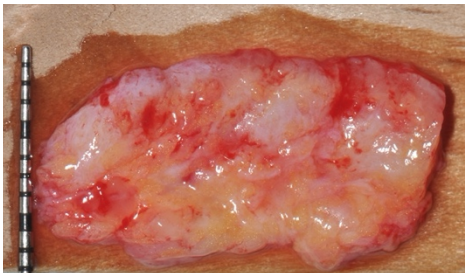


Figure 1

2. STCG from the posterior palate

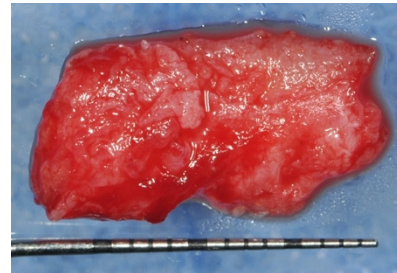


Figure 2

3. DGG from the posterior palate (courtesy of Dr. Sylvie Pereira)

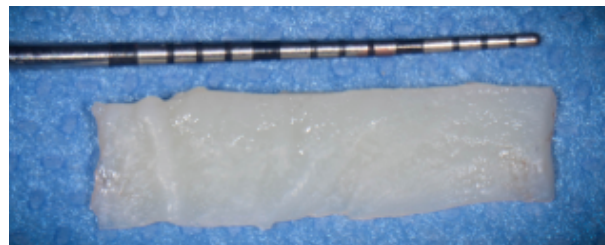


Figure 3

4. TG from the tuberosity area (courtesy of Dr. Sylvie Pereira)

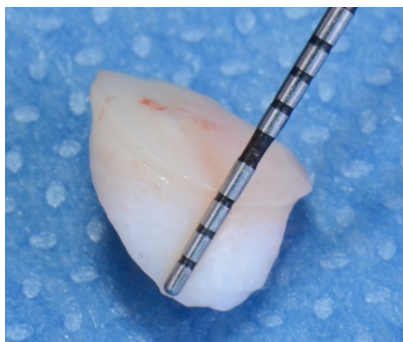


Figure 4

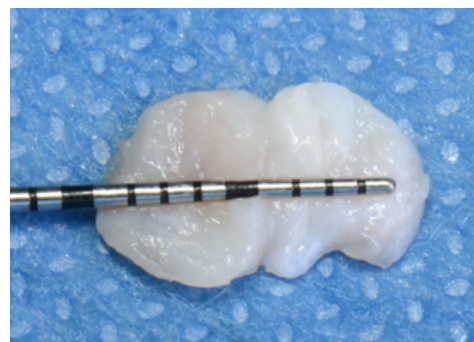


Figure 5

The selection of the donor site depends on existing anatomical limitations, the goal of the procedure, the expected morbidity and the surgeon's expertise. According to the donor site of the gingival autografts there may be differences in the histological composition of the graft and, consequently, will lead to different characteristics that might influence the clinical outcomes (Zucchelli G. et alii. 2020, Zuhr O. et alii. 2014).

Histological differences of gingival autografts of various donor sites and clinical results in mucogingival surgery

The goal of this narrative review is to compare the histological characteristics and clinical results of gingival grafts harvested from the palatal and tuberosity areas, applied in mucogingival surgery procedures.

Development

Anatomical considerations

According to Schroeder's classification of 1986 the oral mucosa is differentiated in 3 types, namely known as the:

- i. non keratinized **lining mucosa** comprising the alveolar mucosa and vestibular fornix, the cheek and lips, the soft palate, the ventral sides of the tongue and the floor of the mouth.
- ii. the **specialized mucosa** of the dorsum of the tongue.
- iii. the **masticatory mucosa** comprising the gingiva and the hard palate mucosa.

The structure of the hard palate epithelium is essentially the same as that of the oral gingival epithelium. Palatal fibromucosa is characterized by a dense connective tissue (CT), known as lamina propria covered by an orthokeratinized epithelium (Schroeder, H.-E. 1981). A layer of fatty and glandular tissue, the submucosa, of varied thickness is present between the palatal fibromucosa and the periosteum covering the palatal bone (Schroeder, H.-E 1986). This is an important difference with the gingiva where a lamina propria is also present but the submucosa is absent (Schroeder, H.-E. 1991).

So, in contrast to the gingiva, large parts of the mucosa of the hard palate contain a layer of submucosa. Going further into the characteristics of this layer, the thickness varies according to different locations in the palate. Near the gingival margin there is considerable lamina propria, however towards the palatal raphe the lamina propria becomes thinner and a submucosa layer is now present, composed of adipose tissue and small mucous glands. The extension of this adipose tissue of the hard palate is until the premolar area, whereas the glandular tissue extends to the soft palate (Redman S. et alii. 1965). The palatine glands can make up 50– 60% of the volume of the hard palate mucosa (Reddy C. et alii. 1976)

Histological differences of gingival autografts of various donor sites and clinical results in mucogingival surgery

Harvesting safety zone

When considering harvesting a graft from the palate, anatomic characteristics should be taken into consideration.

Reiser et al. in 1996 classified the palatal vaults according to height as high, average, or shallow in a study using cadavers. Different anatomic dimensions of the palatal vault would determine the height, length, and thickness of donor tissue that can be obtained. The greatest height (inferior-superior dimension) can be found in the high (U-shaped) palatal vault and the greatest length (anterior-posterior dimension) in a large palate. The thickest tissue can be found in the area from the mesial line angle of the palatal root of the first molar to the distal line angle of the canine.

Additionally, the authors also reported neurovascular findings. The greater and lesser palatine nerves and blood vessels gain entrance into the palate by passing through the greater and lesser palatine foramina. The foramina locations vary, but generally can be identified apical to the third molar at the junction of the vertical and horizontal parts of the palatine bone. These nerves and vessels course anteriorly within a bony groove and the neurovascular bundle may be located 7 to 17 mm from the cemento-enamel junctions (CEJ) of the maxillary premolars and molars (Reiser GM. et alii. 1996)

The mean height of the palatal vault (the shortest distance between the midline of the hard and soft palates and the CEJs of the first molars) in an adult male is 14,90 mm, with a standard deviation of 2.93 mm. The mean height in an adult female is 12,70 mm, with a standard deviation of 2.45 mm (Redman S. et alii. 1965).

When the palatal vault is shallow (flat), neurovascular structures will be located more proximally to the CEJ, at an average distance of 7mm. When the palatal vault is high (U-shaped), the structures will be located at an average greater distance of 17mm from the CEJ. The retrieval of donor tissue from the premolar region in the high and average palate (average distance of 12mm) offers a greater margin of safety than retrieval from the shallow (flat) palatal vault in reference to the neurovascular structures (Reiser GM. et alii. 1996).

Histological differences of gingival autografts of various donor sites and clinical results in mucogingival surgery

Another study measured the distance to the neurovascular structures on 345 patients with cone beam computed tomography, from the canine to the second molar. The results confirmed a distance to the neurovascular bundle greatest at the first molar region (14.02 mm) and shortest at the canine site (10.84 mm) (Yilmaz HG. et alii. 2015). The same correlation to the shape of the palatal vault was found as in Reiser's (1996) study. Based on the findings of the location of the neurovascular structures in the canine area, the authors recommend not to extend graft harvesting from the first premolar (Yilmaz HG. et alii. 2015).

These findings are corroborated by a recent systematic review, where a safety zone for graft harvesting is proposed based on the review of 26 papers (Tavelli L. et alii. 2019). The authors considered the mean measures of the included studies regarding the course of the great palatine artery to the CEJ of each tooth and then subtracting the standard deviation of the mean from the mean values themselves (9.9 ± 2.9 mm in the canine, 11.8 ± 2.2 mm in the first premolar, 13.8 ± 2.1 mm in the second premolar, 13 ± 2.4 mm in the first molar and 13.9 ± 1 mm in the second molar). The safety zone is therefore determined by subtracting to these values of each tooth the standard deviation (to reduce the possibility of injury to the vessel as much as possible) and also subtracting 2mm, corresponding to the gingival margin in a healthy periodontium (Tavelli L. et alii. 2019).

Thickness of palatal mucosa

The thickness of the palatal masticatory mucosa has been analyzed by different methods to study the potential as donor site. In 1997, Studer et alii. measured, with sound probing (PCP UNC 15, Hu-Friedy, Chicago IL), 31 periodontally healthy fully dentate subjects to identify appropriate regions for graft harvesting. The mean thickness in the tuberosity was significantly larger (5.7mm), compared to the mean thickness in the hard palate (3.9mm in the first premolar and 1.8mm in the first molar), without any differences in gender in both areas. The authors report that in the tuberosity area there is a narrow width of keratinized gingiva that may affect the quantity of keratinized tissue that can be harvested.

On the other hand, the palatal area at the first molar presents the limitations of being significantly thinner than any other area. In the year 2000 Muller et alii. measured the palatal mucosa of 40 subjects with an ultrasonic device and also found that mucosal thickness was

Histological differences of gingival autografts of various donor sites and clinical results in mucogingival surgery

thinnest in the region of the first molar (2.1mm). In this study a thinner palatal mucosa was registered in all areas (2.9mm in the premolar area, 2.1mm in the molar area and 4.17mm in the tuberosity area), in comparison to Studer et alii. (1997) that can be attributed to the different measuring technique. In addition, they measured the central and lateral incisor region of the palatal mucosa with a mean thickness of 2.42mm. Muller et alii. (2000) found that females had significantly thinner mean masticatory mucosa than males, while Studer et alii. (1997) found no difference between genders.

Furthermore, in the study of Wara-aswapati et alii. (2001) in 61 subjects, using the same method of measurement as Studer et alii. (1997), they found a significantly thinner mucosa (mean 2.8 ± 0.3 mm) in the younger age group (14 to 21 years) than in the older age group (30 to 59 years) (mean 3.1 ± 0.3 mm). Also, females had a thinner mucosa than males in the same age group, but the difference was not statistically significant.

Computerized tomography can also be used for measuring the palatal mucosa. Based on measurements of 100 patients, females were found to have significantly thinner mean masticatory mucosa (3.66mm) than males (3.95mm). Additionally, the mean thickness of the palatal masticatory mucosa increased with age and according to tooth site. The first molar region was the thinnest (3.13 mm), and the second premolar region was the thickest (3.81 mm). The ratio of palatal width/palatal depth was obtained and results confirmed that there was not a significant difference on tissue thickness between the high and low palatal vaults (Song JE. et alii. 2008).

To summarize the trends of palatal thickness, it appears that can vary according to gender, age and location. Most studies point that females have a significantly thinner mean masticatory mucosa than males (Müller HP. et alii. 2000, Wara-aswapati N. et alii. 2001, Song JE. et alii. 2008). The thickness also seems to increase with age (Wara-aswapati N. et alii. 2001) and varies among tooth site area (Studer SP. et alii. 1997, Müller HP. et alii. 2000, Wara-aswapati N. et alii. 2001, Song JE. et alii. 2008), concluding that the thinnest region is located at the first molar and the thickest is, if available, the tuberosity and if not the premolar area of the palate.

Histological differences of gingival autografts of various donor sites and clinical results in mucogingival surgery

Histological studies on gingival grafts

The detailed anatomical knowledge regarding the thickness of the palatal mucosa and of the lamina propria and the location of the submucosa is a prerequisite for the selection of the treatment method and determination of potential prognosis, such as the likelihood of revascularization or tissue atrophy during recovery (Yu SK. et alii. 2013, Zucchelli, G. et alii. 2010).

Sullivan and Atkins (1968) emphasized the exclusion of the submucosa in a palatal graft, since it was considered that the adipose tissue included in a graft could function “as a barrier both to diffusion and vascularization and therefore should be removed with a scalpel before grafting”.

Proportion Of Lamina Propria And Submucosa

The proportion of lamina propria and submucosa in STCGs was analyzed by Harris in 2003 in 30 patients where a CTG was obtained with a parallel incision technique. The closest section to the incision was analyzed in five locations as regards its composition. A mean of 3.2mm of depth of lamina propria and 2.0mm of submucosa was reported, representing a 65.2% of lamina propria and 34.8% of submucosa. In some cases, the entire graft was lamina propria, containing no submucosa or adipose tissue, while in other grafts the situation was inverse, meaning there was only a minimal depth of lamina propria at the incisal edge. In spite of these histological differences, between some of the grafts in this study, there were no implications on clinical success, regarding root coverage results and aesthetics.

The author also remarks that to achieve more lamina propria in the graft the operator should approach the more superficial plane, since a graft taken from deeper planes will have increased submucosa and adipose content. Finally, it is also to be highlighted that the variability of the composition of the graft may be also due to inter-patient variability, since all grafts were taken with the same technique, from the canine to the 1 molar (Harris, R. J. 2003).

Histological differences of gingival autografts of various donor sites and clinical results in mucogingival surgery

Lamina Propria Thickness

The cadavers study by Sun-Kyoung Yu et alii. (2013) analyzed histomorphometrically the width of the lamina propria. The thickness decreased from the alveolar crest towards the midpalatal suture at all tooth sites (2.06 ± 0.70 at the alveolar crest, $1.54\text{mm} \pm 0.48$ at 4mm and 1.28 ± 0.46 mm at 8mm from the alveolar crest). This is in agreement with the anatomical descriptions of Schroeder (1991). In this study the thickness of the palatal mucosa did not differ significantly between different tooth sites, still the molar area was the thinnest, as observed in other studies. However, the thickness of the lamina propria including the epithelium did differ according to tooth site, being greatest at the distal surface of the first molar (1.92 ± 0.67 mm) and smallest at the distal surface of the second molar (1.32 ± 0.76 mm). This indicates that although the total thickness of palatal mucosa is thinnest at the site of the first molar, it's composition is mainly lamina propria and very little submucosa. On the contrary, in the premolar area there is more overall thickness but less lamina propria and more adipose tissue, responsible for the thickness in this area. This is referred to as the quality of the tissue.

Tuberosity Grafts

The tuberosity graft was first introduced by Hirsh A. in 2001, where the grafting technique was associated with pocket depth reduction surgery. Afterwards, in 2008, Jung performed the histology analysis of a tuberosity graft in a patient treated for a single recession in a superior canine. The recession was treated with a pouch technique combined with a deepithelized tuberosity graft. After 3 months, due to a bulky aspect of the area, gingivoplasty was performed and a biopsy was obtained for the histologic analyses (Jung UW. et alii. 2008).

The histological findings revealed that the connective tissue grafted was denser than the original connective tissue, demonstrating a change to a thick phenotype.

Histological differences of gingival autografts of various donor sites and clinical results in mucogingival surgery

Histological and Clinical studies comparing palatal *versus* tuberosity grafts

Dellavia et alii., (2014) compared the clinical outcomes of localized alveolar ridge augmentation with soft tissue harvested from either the palate or tuberosity, at 1 month and 1 year after surgery. The study involved 14 patients that had a Class I ridge defect, divided into 2 groups, one group received a graft from the palate premolar area (group A) and the other group from the tuberosity (group B). All grafts had a thickness of 3,5mm before adipose tissue and epithelium were removed. The gingival tissues grafted with palatal mucosa showed a significant initial shrinkage or contraction but remained stable over time with a good esthetic result. In contrast, the gingival tissues grafted with tuberosity CT were dimensionally stable in the first few months, then progressively tended to a hyperplastic reaction and assumed a not esthetically pleasing white tissue patch appearance. The pre-surgery measures of thickness of the oral mucosa was 2mm for both groups and at 1 month post-surgery the difference in thickness was not significant, being 5.5 ± 0.3 mm for group A and 5.8 ± 0.2 mm for group B. After 1 year post-surgery there was a difference of almost 2mm in thickness in favor of group B with 6.8 ± 1.1 mm vs 4.9 ± 0.6 mm in group A.

LH2b gene expression was investigated, since this is the major form expressed in all tissues and is generally overexpressed in fibrotic processes. The molecular analyses of the LH2b/COL-I mRNA demonstrated a four-fold increase in fibroblasts from the tuberosity grafts. MMP-1 activity was downregulated in half of tuberosity cell culture supernatants, suggesting reduced interstitial collagen degradation and the concomitant tendency to a higher LH2b/COL-I mRNA ratio could represent a relevant mechanism likely responsible for collagen accumulation in the tuberosity connective compartment (Dellavia C. et alii. 2014).

Rojo et alii. (2018) compared the tuberosity graft with a SCTG taken from the premolar area of the palate. 32 patients with single tooth implants with localized buccal volume deficiency were included. Patients were randomized to receive either a tuberosity graft or a SCTG. An intracrevicular incision extending to both adjacent teeth was performed to raise a split thickness flap and perform the ridge augmentation procedure. Grafts were harvested with a double-bladed scalpel handle to ensure a 1.5mm thickness and were deepithelized afterwards.

Histological differences of gingival autografts of various donor sites and clinical results in mucogingival surgery

The soft tissue volume assessment was performed with an intraoral optical scanner to obtain stereolithography data at baseline and 3 months post-surgery. The authors did not find a statistically significant difference in volume gain, but it was detected a tendency for better results in favor of the tuberosity graft. The distance between the preoperative and postoperative soft tissue profile was measured from 1 to 7mm, in an apical direction from the healing abutment by superimpositions of intraoral optical scans. The mean horizontal contour increased $0.69\pm 0.23\text{mm}$ in the STCG sites and $0.79\pm 0.1\text{mm}$ in the tuberosity site, with no statistically significant difference. But when analyzing the results individually, at 6 mm (of $0.39\pm 0.24\text{mm}$ vs. $0.81\pm 0.33\text{mm}$) and 7mm ($0.25\pm 0.13\text{mm}$ vs. $0.71\pm 0.24\text{mm}$) apically the difference was statistically significant, favoring the tuberosity group.

In 2019, Sanz-Martín et alii. reported the histological findings of the previous randomized controlled clinical trial (Rojo E. et alii. 2018). The results demonstrated that lamina propria represented 51.08% in the palatal group and 72.79% in the tuberosity group, of the total area of the respective grafts, being these differences statistically significant. The area of submucosa represented 4.89% of the total sample in the tuberosity group, while in the palatal group it was 25.75% of the total sample (statistically significant difference).

Another comparison can be made between tuberosity grafts and DGG harvested from the lateral palate in root coverage procedures. Amin et alii. (2018) included 20 patients that had bilateral sites of gingival recession Class I, II and III of Miller. 10 patients were treated with 20 FGG, 10 grafts taken from the tuberosity and 10 grafts taken from the contralateral palate. The other 10 patients were treated with 20 CTG deepithelized extraorally, similarly 10 grafts were from the tuberosity and 10 from the contralateral palate. All grafts were harvested at 1.5mm thickness using a double blade scalpel handle, the deepithelized grafts were of 1mm after epithelial removal. The measurements of thickness were performed at 8 weeks in the center of the grafted area mesiodistally and apicocoronally with an endo file with a stopper and using an endo ruler. The mean gingival thickness of the healed tuberosity grafts was statistically significantly greater than those of the palatal grafts ($2.9\pm 0.5\text{mm}$ vs. $2.3\pm 0.6\text{mm}$ ($p=0.016$)) in the deepithelized grafts and $2.7\pm 0.7\text{mm}$ vs. $2.1\pm 0.7\text{mm}$ ($p=0.026$) in the FGGs).

Histological differences of gingival autografts of various donor sites and clinical results in mucogingival surgery

Discussion

The goal of this thesis was to compare the histology and clinical results of autogenous gingival grafts from different harvesting sites used in mucogingival surgical procedures. Grafts harvested from the palate and the tuberosity were compared, analyzing how their composition at a histological level correlate with the following clinical parameters: postoperative shrinkage, volume gain, long term stability, width of keratinized tissue gain, aesthetics and morbidity.

Few clinical and histological studies were found in the literature that compare palate grafts *versus* tuberosity grafts. The included studies in this review refer to mucogingival surgical procedures that include ridge augmentation procedures, as well as root coverage procedures, and both histological and clinical studies were considered (Amin PN et alii. 2018, Dellavia C. et alii. 2014, Rojo E. et alii. 2018, Sanz-Martín I et alii. 2019).

Histological studies showed a fair difference between the tuberosity graft and the palate graft. The tuberosity graft has lamina propria in its whole dimension, however the SCTG of the palatal area contains higher amounts of lamina propria closer to the gingival margin, whereas more apically it contains more glandular and fatty tissue (Bertl K et alii. 2015, Sanz-Martín I et alii. 2019, Yu SK. et alii. 2013). These differences in graft composition may influence the pos-operative shrinkage and, as a consequence, influence volume gain. The lower post-operative tissue contraction of tuberosity grafts was already suggested by Jung et al. in 2008 and is in agreement with Zhur et alii. (2014) that refers that STCGs from the tuberosity seemed to be denser and firmer than those harvested from the anterior palate and consequently, they would be less susceptible to post-operative shrinkage.

Furthermore, this is also reported in the study of Sanz-Martín et alii. (2019) that described a tendency that the tissue from the tuberosity area seems to be denser and thicker, with more collagen and less fat and glandular tissue, in comparison to grafts harvested from the anterior lateral palate. Their results regarding the collagen content are in agreement with those published by Dellavia et alii. (2014). The study disclosed that COL-1 and COL-3 gene expressions were found to be lower in the tuberosity, when compared to palatal fibroblast and, although MMP1 and MMP2 expressions were similar, differences were found regarding LH2b/COL-1 ratio, suggesting that tuberosity-derived collagen could be more susceptible to cross-linking and therefore less likely to be degraded by MMPs. The authors concluded that the maxillary tuberosity is a valid donor site for harvesting a soft tissue graft and it may provide

Histological differences of gingival autografts of various donor sites and clinical results in mucogingival surgery

advantages compared with the palate, mainly a higher increase in soft tissue thickness and in the width of keratinized tissue. The differences in keratinized tissue gain were shown to be statistically significant in favor of the tuberosity graft in the study of Rojo et alii. (2018), where values of $0.87\pm 0.99\text{mm}$ versus $1.28\pm 0.67\text{mm}$ were found for SCTGs and tuberosity graft respectively.

In the consensus report of Group 3 of the 10th European Workshop on Periodontology in 2014 it is stated that clinical experience recommends harvesting SCTGs from the posterior palate when better volume stability over time is desired, such as in soft tissue augmentation procedures. On the other hand, this type of graft seems to be more sensitive to the local blood supply for its revascularization (Zuhr O. et alii. 2014).

The post-operative tissue stability, following ridge augmentation procedures, was found to be enhanced in tuberosity grafts. Dellavia et alii. (2014) demonstrated that SCTGs displayed a reduction in volume, whereas, in contrast, the tuberosity grafts had a dimensional stability after 1 year post-surgery. The increase in the thickness of oral mucosa from 2mm pre-surgery to $4.9\text{mm}\pm 0.6\text{mm}$ for the SCTGs and to $5.6\pm 0.8\text{mm}$ for the tuberosity grafts after 1 year post-surgery. This trend was also reported by Rojo et alii. (2018), reporting a mean horizontal contour increased of $0.69\pm 0.23\text{mm}$ in the STCG sites versus $0.79\pm 0.1\text{mm}$ in the tuberosity site, with a statistically significant difference at 6 mm (of $0.39\pm 0.24\text{mm}$ vs. $0.81\pm 0.33\text{mm}$) and 7mm ($0.25\pm 0.13\text{mm}$ vs. $0.71\pm 0.24\text{mm}$) apically. This is also in agreement with Amin et alii. 2018 study where the mean gingival thickness of the healed tuberosity grafts was statistically significantly greater than those of the palatal grafts ($2.9\pm 0.5\text{mm}$ vs. $2.3\pm 0.6\text{mm}$ ($p=0.016$) in the deepithelized grafts and $2.7\pm 0.7\text{mm}$ vs. $2.1\pm 0.7\text{mm}$ ($p=0.026$) in the FGGs).

On the other hand, the comparison of palatal to tuberosity grafts on root coverage procedures revealed no statistically significant differences, as regards mean percentage of root coverage, although results were slightly in favor of tuberosity grafts ($67\pm 12\%$ versus $62\pm 13\%$) at 8 weeks post-operative (Amin PN et alii. 2018). More studies are needed as regards root covering procedures comparing both types of grafts.

It is also crucial to report and compare the aesthetic outcome. The use of tuberosity grafts may result in an excessive augmentation in volume and unaesthetic whiter color

Histological differences of gingival autografts of various donor sites and clinical results in mucogingival surgery

(Arcidiacono A. et alii. 2001, Jung UW. et alii. 2008), when compared with a STCG graft. The gingival tissues grafted with tuberosity CT although dimensionally stable in the first few months, progressively tended to a hyperplastic reaction and assumed a not esthetically pleasing white tissue patch appearance (Dellavia C. et alii. 2014).

Additionally, the aesthetics outcomes of root coverage procedures are highly related to tissue change, in thickness and size, that occur over time. Zucchelli et alii. (2003) analyzed the outcomes of a graft less than 1mm of thickness and with an apico-coronal dimension that covered until the bone dehiscence in comparison to a graft 3mm higher than the bone dehiscence and with a thickness greater than 1mm. A higher percentage of root coverage was achieved with the thinner and smaller graft, although not statistically significant, and better aesthetics and lower patient morbidity. This is due to the fact that a bigger and thicker graft represents a bigger obstacle for blood supply. Later, in 2014, Zucchelli et alii. compared again an even smaller graft of 4mm apico-coronally that did not cover completely the bone dehiscence with one that reach to cover the whole bone dehiscence with the same differences in thickness as the previous study. Better aesthetics results were obtained for the thinner and smaller grafts, assessed by an expert periodontist and also acknowledge by the patients, in terms of color match and keloid formation.

Regarding patient morbidity, tuberosity grafts appear to be related to lower levels of post operative pain in the donor site, in comparison to a SCTG harvested from the palate. This tendency may be related to less friction during eating in the tuberosity area as is the palate. On the other hand, there is not a direct contact between the tongue and the tuberosity, unlike what may occur with the palate (Amin PN et alii. 2018).

Another factor to consider related to post-operative pain is the harvesting technique. Several clinical studies (Farnoush, A. 1978, Griffin, T. et alii. 2006, Jahnke, P. et alii. 1993, Wessel, J. et alii. 2008) report more post-operative pain in FGGs than SCTGs. The reason may be related to differences in healing, since SCTGS heal by primary intention while the FGGs heal by secondary intention. Nevertheless, Zucchelli et alii. 2014 and Burkhardt et alii. 2015 demonstrated that post-operative pain was rather influenced by the thickness of the graft and the remaining soft tissue at the palate and not by the healing obtained at the donor site. What has to be clarified is that some of the first studies may have taken into account deeper FGGs,

Histological differences of gingival autografts of various donor sites and clinical results in mucogingival surgery

in correspondence to the original technique where a wider graft was expected to be obtained. This is a big difference on how nowadays a FGGs is taken to be then deepithelized extraorally.

It is important to highlight that considering the palatal donor site, there can also be additional differences in the histological characteristics of the graft related to the harvesting technique. In fact, Bertl et alii. (2015) reported that a DGG, where tissue is taken from a more superficial aspect of the palate will consist mainly of lamina propria, that contains much larger amounts of fibrous connective tissue and much lower amounts of fatty-glandular tissue, compared to a split flap graft taken from a deeper aspect of the palate that will consist mainly of the submucosa. In a randomized clinical trial the clinical outcomes achieved by either DGGs or SCTGs points to a statistically significant difference in the increase of gingival thickness of 1.32 mm with SCTGs *versus* 1.55mm in patients treated with a DGG. The authors relate this result to a better quality of tissue, better stability and less shrinkage of DGG (Zucchelli, G. et alii. 2010). In a systematic review and meta analyses results were slightly in favor of the CAF + DGG compared to CAF + SCTG, being the pooled weighted mean of the root coverage percentage of 94.0% *versus* 91.7%, respectively. It was concluded that the DGG approach may be favored for obtaining autologous CTG (Tavelli L. et alii. 2019).

The FGG approach can also be performed in clinical situations with a very thin masticatory mucosa, thereby not involving blood vessels and nerve fibers running in deeper layers. By applying this technique, high quality tissue layer of the lamina propria can be used to its full extent as no parts of it remain in the flap at the donor site like it would happen if a trap door technique was performed where a good portion of the lamina propria would remained in the flap (Zuhr O. et alii. 2014).

The histological composition of the graft is paramount when choosing the harvesting site, being this composition of better quality when having lamina propria in contrast to submucosa (fatty and glandular tissue). This is found to be true in tuberosity grafts and correlate to better clinical results as regards volume gain and stability, gain in the width of keratinized tissue and less patient morbidity. On the other hand, STCGs are superior when comparing to the tuberosity grafts in terms of availability and aesthetics.

Histological differences of gingival autografts of various donor sites and clinical results in mucogingival surgery

As a final remark, there are few studies comparing tuberosity to palatal grafts in mucogingival procedures and, therefore, there is a clear need to perform well design randomized clinical trials to further elucidate potential differences in clinical outcomes.

Conclusion

From the literature analysis included in this review it is concluded that the location of the donor site (anterior or posterior palate, including the tuberosity) and the grafting technique, (a superficial or deeper graft) can affect the graft composition, which may have an impact in the clinical results of mucogingival procedures.

The tuberosity area as a donor site presents several advantages: simple grafting technique, low morbidity and discomfort for the patient, easier hemostasis control, minimal tissue contraction after healing and consequent tissue stability over time. Disadvantages are related to the quantity of tissue available, and consequent graft dimensions, and a limited aesthetic outcome.

Histological differences of gingival autografts of various donor sites and clinical results in mucogingival surgery

Bibliographical references

1. Amin PN et alii. (2018) Tuberosity versus palatal donor sites for soft tissue grafting: a split- mouth clinical study. *Quintessence International*, 49(7), pp. 589-598.
2. Arcidiacono A, Ricci G. (2001). Clinical and Histomorphologic Analysis After Ridge Augmentation Using Connective Tissue Obtained Either From the Tuber Maxillae or From the Palate: A One Year Evaluation. *Proceedings of the XII International Congress of the SIDP* (Società Italiana di Parodontologia e Implantologia), Florence, 57–61.
3. Bertl K et alii. (2015). Relative composition of fibrous connective and fatty/ glandular tissue in connective tissue grafts depends on the harvesting technique but not the donor site of the hard palate. *Journal of Periodontology*, 86(12), pp. 1331–1339.
4. Bruno JF. (1994). Connective tissue graft technique assuring wide root coverage. *The International Journal of Periodontics & Restorative Dentistry*, 14(2), pp. 126-137.
5. Burkhardt R, Hammerle CH, Lang NP. (2015). Research group on oral soft tissue biology, and wound healing. Self-reported pain perception of patients after mucosal graft harvesting in the palatal area. *Journal of Clinical Periodontology*, 42(3), pp. 281-28.
6. Dellavia C. et alii. (2014) Human Palatal and Tuberosity Mucosa as Donor Sites for Ridge Augmentation. *The International Journal of Periodontics & Restorative Dentistry*, 34(2), pp. 179-186.
7. Edel, A. (1974). Clinical evaluation of free connective tissue grafts used to increase the width of keratinised gingival. *Journal of Clinical Periodontology*, 1(4), pp. 185–196.
8. Farnoush, A. (1978) Techniques for the protection and coverage of the donor sites in free soft tissue grafts. *Journal of Periodontology*, 49(8), pp. 403– 405.
9. Griffin, T. J., Cheung, W. S., Zavras, A. I. & Damoulis, P. D. (2006). Postoperative complications following gingival augmentation procedures. *Journal of Periodontology*, 77(12), pp. 2070–2079.
10. Harris RJ. (1992). The connective tissue and partial thickness double pedicle graft: A predictable method of obtaining root coverage. *Journal of Periodontology*, 63(5), pp. 477-486.
11. Harris, R. J. (2003) Histologic evaluation of connective tissue grafts in humans. *The International journal of periodontics & restorative dentistry*, 23(6), pp. 575–583.
12. Hirsch A, Attal U, Chai E, Goultschin J, Boyan BD, Schwartz Z. (2001). Root coverage and pocket reduction as combined surgical procedures. *Journal of Periodontology*, 72(11), pp. 1572-1579.
13. Hurzeler, M. B. & Weng, D. (1999). A single-incision technique to harvest subepithelial connective tissue grafts from the palate. *The International journal of periodontics & restorative dentistry*, 19(3), pp. 279–287.
14. Jahnke, P. V. et alii. (1993). Thick free gingival and connective tissue autografts for root coverage. *Journal of Periodontology*, 64(4), pp. 315–322.
15. Jung UW, Um YJ, Choi SH. (2008). Histologic observation of soft tissue acquired from maxillary tuberosity area for root coverage. *Journal of Periodontology*, 79(5), pp. 934–940.
16. Langer B, Langer L. (1985). Subepithelial connective tissue graft technique far root coverage. *Journal of Periodontology*, 56(12), pp. 715-720.
17. Lorenzana ER, Allen EP. (2000). The single-incision palatal harvest technique: a strategy for esthetics and patient comfort. *The International Journal of Periodontics & Restorative Dentistry*, 20(3), pp. 297-305.
18. Müller HP, Schaller N, Eger T, Heinecke A. (2000). Thickness of masticatory mucosa. *Journal of Clinical Periodontology*, 27(6), pp. 431-436.

Histological differences of gingival autografts of various donor sites and clinical results in mucogingival surgery

19. Reddy, C. R. R. M., Venkatarathnam, G. & Kameswari, V. R. (1976). Distribution of glands in the mucosa of the hard palate and its relation to carcinoma. *Journal of Oral Surgery*, 34(3), pp. 232–236.
20. Redman S. Shapiro BL, Gonlin RJ. (1965). Measurement of normal and reportedly malformed palatal vaults: Normal juvenile measurements. *Journal of Dental Research*, 45(2), pp. 266-267.
21. Reiser GM, Bruno JF, Mahan PE, Larkin LH. (1996). The subepithelial connective tissue graft palatal donor site: Anatomic considerations for surgeons. *International Journal of Periodontics Restorative Dentistry*, 16(2), pp. 130-137.
22. Rojo E. et alii. (2018). Soft tissue volume gain around dental implants using autogenous subepithelial connective tissue grafts harvested from the lateral palate or tuberosity area. A randomized controlled clinical study. *Journal of Clinical Periodontology*, 45(4), pp. 495-503.
23. Sanz M, Simion M. (2014). Surgical techniques on periodontal plastic surgery and soft tissue regeneration: consensus report of Group 3 of the 10th European Workshop on Periodontology. *Journal of Clinical Periodontology*, 41(Suppl. 15)pp. S92–S97.
24. Sanz-Martín I et alii. (2019). Structural and histological differences between connective tissue grafts harvested from the lateral palatal mucosa or from the tuberosity area. *Clinical Oral Investigations*, 23(2), pp. 957-964.
25. Schroeder, H.-E. (1981). *Differentiation of human oral stratified epithelia*. Basel, Karger.
26. Schroeder, H.-E (1986) The periodontium. In: Oksche, A. & Vollrath, L. *Handbook of microscopic anatomy*, Berlin, Springer, vol. 5, pp. 233–246.
27. Schroeder, H.-E. (1991) *Oral structural biology*. New York, Georg Thieme Verlag.
28. Song JE. et alii. (2008). Thickness of posterior palatal masticatory mucosa: The use of computerized tomography. *Journal of Periodontology*, 79(3), pp. 406–412.
29. Studer SP. et alii. (1997). The thickness of masticatory mucosa in the human hard palate and tuberosity as potential donor sites for ridge augmentation procedures. *Journal of Periodontology*, 68(2), pp. 145-151.
30. Sullivan, H. C., Atkins, J. (1968). Free autogenous gingival. I. Principles of successful grafting. *Periodontics*, 6(1), pp. 5-13.
31. Tavelli L. et alii. (2019). Comparison between Subepithelial Connective Tissue Graft and De-epithelialized Gingival Graft: A systematic review and a meta-analysis. *Journal of the International Academy of Periodontology*, 21(2), pp. 82–96.
32. Tavelli L. et alii. (2019). What Is the Safety Zone for Palatal Soft Tissue Graft Harvesting Based on the Locations of the Greater Palatine Artery and Foramen? A Systematic Review. *Journal of Oral and Maxillofacial Surgery*, 77(2), pp. 271-271.
33. Wara-aswapati N. et alii. (2001). Thickness of palatal masticatory mucosa associated with age. *Journal of Periodontology*, 72(10), pp. 1407-1412.
34. Wessel, J. R. & Tatakis, D. N. (2008). Patient outcomes following subepithelial connective tissue graft and free gingival graft procedures. *Journal of Periodontology*, 79(3), pp. 425–430.
35. Yilmaz HG, Ayali A. (2015). Evaluation of the neurovascular bundle position at the palate with cone beam computed tomography: an observational study. *Head and Face Medicine*, 11:39, pp. 1-5.
36. Yu SK. et alii. (2013). Histomorphometric analysis of the palatal mucosa associated with periodontal plastic surgery on cadavers. *Surgical and Radiologic Anatomy* 35(6), pp. 463–469.
37. Zucchelli, G. et alii. (2003). Bilaminar techniques for the treatment of recession-type defects. A comparative clinical study. *Journal of Clinical Periodontology*, 30(10), pp. 862–870.

Histological differences of gingival autografts of various donor sites and clinical results in mucogingival surgery

38. Zucchelli, G. et alii. (2010). Patient morbidity and root coverage outcome after subepithelial connective tissue and de-epithelialized grafts: a comparative randomized-controlled clinical trial. *Journal of Clinical Periodontology*, 37(8), pp. 728–738.
39. Zucchelli G. et alii. (2014). Does the dimension of the graft influence patient morbidity and root coverage outcomes? A randomized controlled clinical trial. *Journal of Clinical Periodontology*, 41(7), pp. 708–716.
40. Zucchelli G, Mounssif I. (2015). Periodontal plastic surgery. *Periodontol 2000*, 68(1), pp. 333-368.
41. Zucchelli G. et alii. (2020). Autogenous soft tissue grafting for periodontal and peri-implant plastic surgical reconstruction. *Journal of Periodontology*, 91(1), pp. 9–16.
42. Zuhr O, Baumer D, Hurzeler M. (2014). The addition of soft tissue replacement grafts in plastic periodontal and implant surgery: critical elements in design and execution. *Journal of Clinical Periodontology*, 41(Suppl 15), pp. S123-S142.